

New Treatments for Degenerative Tendinopathy, focused on the Region-Specific of the Tendon

Jose Manuel Sánchez-Ibáñez^{1,2*}, Maria Elisa Fernández¹, Joan Carles Monllau^{3,4}, Ángel Alonso-Díez², Jesús Sánchez-García² and Jose Luis Sánchez-Sánchez⁵

¹Department of Sports Rehabilitation, CEREDE Sports Medicine and Rehabilitation Clinic, Barcelona, Spain

²Department of Medicine, Surgery and Anatomy, University of León, León, Spain

³Department of Orthopaedic Surgery and Traumatology, Parc de Salut Mar, Universitat Autònoma de Barcelona, Barcelona, Spain

⁴Catalan Institute of Traumatology and Sports Medicine (ICATME), Hospital Universitari Dexeus, Universitat Autònoma de Barcelona, Barcelona, Spain

⁵Department of Physical Therapy, University of Salamanca, Salamanca, Spain

*Corresponding author: Jose Manuel Sánchez-Ibáñez, CEREDE Sports Medicine and Rehabilitation Clinic, C/ Doctor Roux nº 8-10 bajos, Barcelona 08017, Spain, Tel: +34934523510; E-mail: drsanchez@cerede.es

Received date: September 09, 2015; Accepted date: October 20, 2015; Published date: October 26, 2015

Copyright: © 2015 Sánchez-Ibáñez JM, et al. This is an open-access article distributed under the terms of the Creative Commons Attribution License, which permits unrestricted use, distribution, and reproduction in any medium, provided the original author and source are credited.

Abstract

Tendinopathy is a common, painful, overuse disorder associated with a failure of the tendon repair process and has a low potential for healing with the usual techniques. Although many different treatment methods have been described, there is no consensus regarding the optimal treatment for this condition.

Therefore, new treatments for tendinopathies drawn from the existing literature as well as from their own experience dealing with this condition to deal with this delicate pathology have been developed over last few decades. Although some treatments like eccentric training, the EPI[®] technique, extra-corporeal shock wave therapy (ESWT), hyaluronic acid (HA), platelet-rich plasma (PRP) are being established as the main therapeutic models, there are still questions to be answered as well as the need for a clear treatment protocol to be established.

This brief review aims to update recent information on the treatment approaches of tendinopathy focused on the specific area of the tendon.

Keywords: Tendinopathy; EPI[®] technique; Treatment approaches

Introduction

The tendons play an essential role in the musculoskeletal system by transferring the tensile loads from muscle to bone so as to enable joint motion and stabilization [1]. Tendons have the ability to adapt to load changes, increasing collagen synthesis as a result of acute and prolonged physical exercise training [2,3]. Despite this ability to adapt physiological loads, tendinopathies represent a clinical problem which affects both professional and recreational athletes as well as people involved in repetitive work [4,5]. Tendinopathies overuse represents 30% to 50% of all sports injuries and result in a significant amount of morbidity and spending health cost [6]. More than 28 million patients in the United States have tendon damage annually [7]; it is estimated that they could cost the United States health system some \$30 billion per annum [8].

The etiology includes lifestyle, loading pattern, biological variables (genetics, age, sex) as well as different pharmacological agents [9].

The Achilles tendon and patellar tendon are most affected, in both elite and recreational athletes, in sports that heavily load the lower extremities [10]. Achilles tendinopathy is more prevalent in the lower extremity, with a frequency of 5.9% in sedentary and about 50% for endurance athletes [10,11]. Patellar tendinopathy is most common involvement in the knee and its prevalence has been reported to be 44.6% in elite volleyball players [12] and 31.9% in elite basketball

players [13] and also represents two thirds of all pathologies of the knee between these two sports [10].

The traditional model of "tendonitis" as an inflammatory process is now obsolete since the appearance of several publications, which have described the pathological process of the tendon as mainly degenerative (tendinosis) [14,15]. This is justified due to the absence of inflammatory cells, the presence of areas of collagen degeneration, myxoid degeneration and an increase in fundamental substance and is associated with a failure of the tendon repair process [14,15].

Tendinopathy is a clinical diagnosis and typically is based on medical history and clinical findings. Imaging techniques: such as color doppler sonography (CDS) and magnetic resonance imaging (MRI) are valuable tools to confirm the diagnosis and provide guidance for treatment [16].

The tendon injury can occur in the tenotendinous region, as in the Achilles tendon. However, most of the tendon pathology and pain is located in the osteotendinous, such as elbow lateral patellar tendon and the medial epicondyle tendons and tendons in the groin [17]. While osteotendinous and tenotendinous and are morphologically different region in normal state, the occurrence of extracellular matrix pathology induced cellular changes are indistinguishable [18].

Tendinopathies are in the main accompanied by an excessive nociceptive signalling from the tendon, causing pain and restricted mobility [19]. Mechanisms driving these structural and neurological changes are not fully understood. A more recent theory ascribes part of

the tendinosis changes to an increased production of biochemical agents, such as substance P (SP) [20] and NMDAR1 glutamate receptor [20-22].

Overall tendinopathies are characterized by prolonged, localized pain, associated with physical activity requiring cyclic mechanical stimuli. Patients respond poorly to most conservative treatments, however, a broad spectrum of disorders of the tendon within the concept of tendinopathy that share some common characteristics (paratendinitis, tendinitis, tendon overuse injuries, spontaneous tendon rupture, calcifying tendinitis) or gaps, often converge in the same tendon (Figure 1). In this sense, there is no single etiology and pathogenesis that can explain all these processes [17].

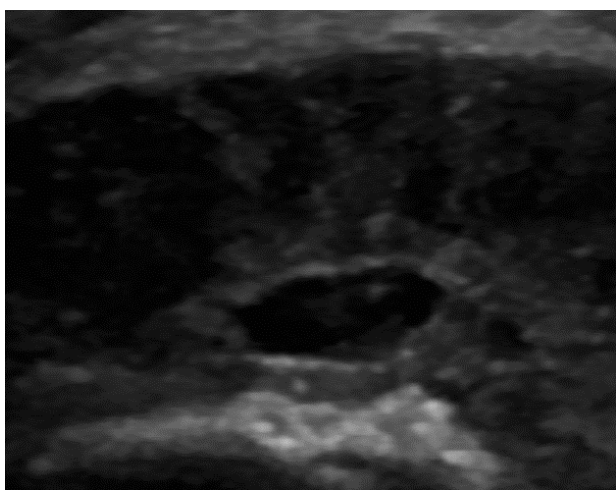


Figure 1: Transverse ultrasound of patellar tendinopathy with area of fibrillar rupture (hypoechoic foci surrounded by connective reinforcement). Tendon degeneration in its most proximal and deep portion (critical area to receive higher tensile strength during tissue stress).

Treatment options have changed over the last decade in parallel to the pathophysiological and histopathological findings in tendinopathies. Since the underlying pathology of chronic tendinopathy can be defined as a "defective healing response", treatment should aim to encourage regeneration of the tendon, pain modulation and the restoration of the biomechanical properties [23,24].

In this paper the authors will update the knowledge about tendinopathy and current treatments focused on the region-specific of the tendon drawn from the existing literature as well as from their own experience dealing with this condition. Some of these treatments are eccentric training, the EPI® technique, extra-corporeal shock wave therapy (ESWT), hyaluronic acid (HA), platelet-rich plasma (PRP) are other treatment options [25].

Anti-inflammatory therapy

Conventional conservative treatments have generally been used empirically to reduce pain and inflammation. These treatments include relative repose or activity modification, cold, stretching, orthopedic supports, physiotherapy and biomechanical correction. They are usually employed initially in acute and the more hyperalgesic phase of

tendinopathy but fail to modify the histological structure of the tendon [26,27].

The aim of non-steroidal anti-inflammatory drugs (NSAIDs) is to reduce inflammation by inhibiting the synthesis of inflammatory factors (inflammatory cells, prostaglandins, interleukins, etc.) and their use has been popular in the management of tendinopathy for years [28]. NSAIDs affect the activity of tenocytes and glycosaminoglycan synthesis [29,30]. While their use can be justified on a reactive tendinopathy, the tendon's response upon loading can be affected by a potential inhibition of collagen synthesis [31] as well as have a detrimental effect on muscle adaptation [32].

Possible mechanisms of action of corticosteroid injection include a reduction in extrinsic or intrinsic inflammation, reduction in the proliferation of tenocytes, anti-angiogenic activity, and the inhibition of scar formation, some anti-nociceptive action or a combination of these mechanisms [33].

The literature suggests that the majority of patients may experience a short-term improvement in terms of pain and/or function but in exchange for a high risk of relapse in the medium term and with side effects that may even lead to a rupture of the tendon [34]. Two recent systematic reviews showed worse results from the use of glucocorticoids in comparison to other treatments and the placebo group in the medium and long-term [35,36].

Konsgaard et al. [37] reported that heavy slow resistance training also resulted in significant improvement compared with corticosteroid injections.

Eccentric exercises

Eccentric exercise has shown to cause an upregulation of insulin-like growth factor (IGF-I). This upregulation of IGF-I is associated with cellular proliferation and matrix remodelling within the tendon [38].

Programs of eccentric exercise have been proposed as a key element in strength training in rehabilitation because they can supposedly counteract the response of defective healing that apparently underlies tendinopathy by promoting the creation of collagen fibers within the tendon [39,40]. The literature places increasing emphasis on the importance of a proper choice of the load used [41].

The continuum model in tendinopathy (reactive tendinopathy, tendon dysrepair and degenerative tendinopathy) provides a reasoned basis for believing that the protocol to be performed depends on the current clinical presentation [17]. The protocol proposed by Alfredson et al. is generally used [39]. It consists of three sets of 15 repetitions, performed twice a day, seven days a week for 12 weeks.

Ohberg et al. [42] examined tendon structure by grey-scale ultrasound in 26 tendons with Achilles tendinosis, which had been treated with eccentric exercise. Remarkably, after a mean follow up of 3.8 years, 19 of 26 tendons had a more normalised structure, as gauged by their thickness and by the reduction of hypochoic areas.

Visnes et al. [43] suggested that eccentric training had a positive effect on patellar tendinopathy and recommended that athletes suspend sports activity during rehabilitation.

The gradual progression from eccentric-concentric to eccentric followed by a faster loading can benefit patients with Achilles tendinopathy cannot start with a program proposed by eccentric

Alfredson et al. [39] due to pain or weakness of the sural triceps muscle [44].

Isoinertial eccentric training (YoYoTechnology AB, Stockholm, Sweden) resulted in an improvement of muscle function and reduced pain in patients with patellar tendinopathy [45]. The combination of EPI® technique and isoinertial eccentric exercise offers good results in the treatment patellar tendinopathy [46].

EPI® technique

In recent years, the intratissue percutaneous electrolysis (EPI®) technique has become more relevant in the scientific literature [46-48] given the good results yielded in the treatment of patellar degenerative tendinopathy in comparison to other previous conservative treatments.

This technique, created by Sánchez-Ibáñez [49,50] and who have over 15 years' experience in its use, uses a flow of cathodic current directed exclusively to the area of degenerated tendon through an ultrasound-guided needle that brings about an organic reaction that leads to rapid regeneration of the degenerated tendon.

The application of ultrasound-guided EPI® technique produces a non-thermal electrochemical reaction centered on degenerated tissue (tendinosis). This leads to a controlled local inflammatory reaction that leads to the regeneration of damaged tissue [48,51].

In experimental studies with human tendon injury, there has been a disproportionate expression of certain cytokines and matrix metalloproteinase (MMPs), prostaglandin E2 (PGE2), interleukin-6 (IL-6) and interleukin-1b (IL-1b) [52,53]. IL-1b in turn increases the production of matrix metalloproteinase-1 (MMP-1), matrix metalloproteinase-3 (MMP-3) and prostaglandin E2 (PGE-2) [53].

A recent experimental study [48] showed that with the use of EPI® technique in patellar tendinopathy increase of anti-inflammatory proteins, like peroxisome proliferator-activated receptor gamma (PPAR-γ). These proteins play a key role in the inhibition of expression of proinflammatory molecules secreted by macrophages, such as tumor necrosis factor alpha (TNF-α), IL-6 and IL-1β, thus producing in the treated tissue a highly beneficial molecular response during degenerative tendinopathy. This, in turn, results in an increase of the expression of vascular endothelial growth factor (VEGF) and vascular endothelial growth factor receptor 2 (VEGFR-2), mediators responsible for angiogenesis anti-inflammatory response. The EPI® technique makes for the activation of molecular and cellular mechanisms of the tendon responsible for phagocytosis and the regeneration of degenerated tissue.

In recent research to evaluate the therapeutic effects EPI® technique on the patellar tendinopathy [46]. The results documented were good and stable with the Victorian Institute of Sport Assessment-Patella (VISA-P) score, Tegner scores and Roles and Maudsley score, and terms of clinical and functional improvement in patellar tendinopathy and providing a follow-up of 10 year.

The EPI® technique (Figure 2) achieves a much localized organic reaction in the clinical focus by using a specially designed device for this purpose (EPI Advanced Medicine®, Barcelona, Spain. EPI® technique videos online: www.epiadvanced.com), which leads to the rapid regeneration of degenerated tissue. This leads to the production of new immature collagen fibers that become mature by means of eccentric stimulus [47], thereby obtaining good results in the short and long-term in terms of pain and function.

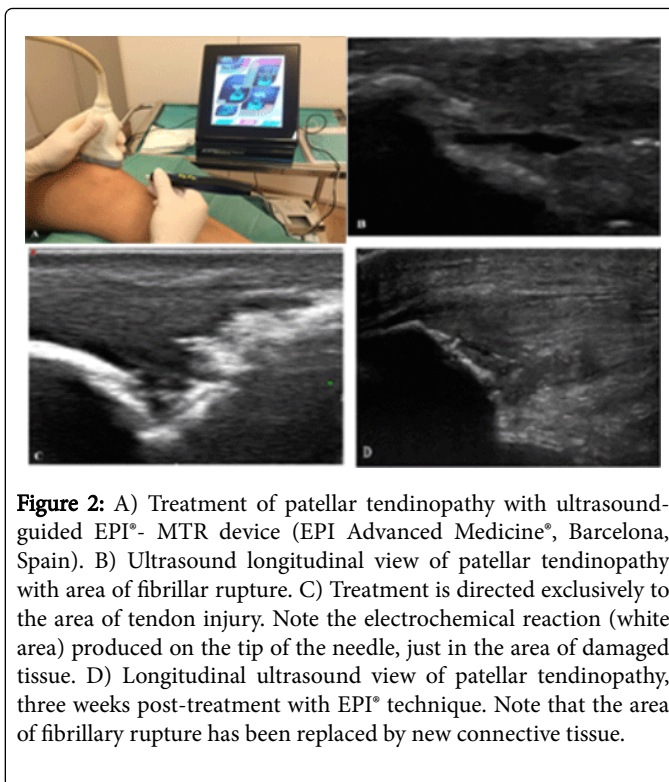


Figure 2: A) Treatment of patellar tendinopathy with ultrasound-guided EPI®- MTR device (EPI Advanced Medicine®, Barcelona, Spain). B) Ultrasound longitudinal view of patellar tendinopathy with area of fibrillar rupture. C) Treatment is directed exclusively to the area of tendon injury. Note the electrochemical reaction (white area) produced on the tip of the needle, just in the area of damaged tissue. D) Longitudinal ultrasound view of patellar tendinopathy, three weeks post-treatment with EPI® technique. Note that the area of fibrillary rupture has been replaced by new connective tissue.

Extra-corporeal shock wave therapy (ESWT)

Several clinical trials have evaluated the use of extra-corporeal shock waves therapy (ESWT) for the treatment of patients with chronic tendinopathy with divergent results [28,54,55]. Multiple variables are associated with this therapy, the type of shock wave generator (electrohydraulic, electromagnetic or piezoelectric), the wave type (radial or focal), the intensity (total energy per shock waves/session), the frequency and the protocol of application and repetitions [56].

Some of the effects of ESWT on tendinopathies like the inhibition of nociception with the release of substances which inhibit pain (endorphins), the increase in the permeability of cell membranes of neurons and cellular damage that could create immediate analgesia have been described [25].

Other biological effects of ESWT described, are the induction of specific growth factors (TGF-β1 and IGF-1) which play an important anabolic and mitogen role, increased blood flow, mediators of the inflammatory process, and increased release of hydroxyproline tenocytes of proliferation and collagen synthesis [57].

However, evidence of the effectiveness of ESWT in the treatment of tendinopathy is inconsistent, still so, it is widely used in sports medicine and physiotherapy [58]. It appears that the combination of treatments may have a synergistic effect and lead to better results. In this sense, a study showed better results by combining the ESWT and eccentric exercises than by performing eccentric exercises alone [59, 60].

Platelet-rich plasma (PRP)

Platelets are nonnucleated cytoplasmic bodies derived from megakaryocyte precursors. They play a pivotal role in hemostasis and wound healing via the formation of fibrin clots. Therefore, increasing platelet concentration in injured tissue and may result in an exponential release of diverse bioactive factors and, subsequently, enhance the healing process [61].

Injections with platelet rich plasma (PRP) has been used for the treatment of tendinopathy with the aim of providing cellular and humoral mediators to induce healing in areas of degeneration. Despite the long road ahead toward establishing an agreed protocol on the use of PRP [62,63], it is a widespread treatment option for the treatment of chronic tendon injuries and its beneficial effects have been demonstrated in several studies [70].

A recent experimental study showed that with the use of PRP in patellar tendinopathy, there was an increase in fibroblasts and bone marrow stem cells inside of and around the injury. Cell proliferation was twice as high and the PRP-treated group also showed a significant increase in type I and III collagen when compared to the control group [64]. Another in vitro study in humans showed that following the application of PRP, there was increased cellular proliferation, collagen production in tenocytes, an overexpression of the receptor of vascular endothelial growth factor-A (VEGF-A) and an increase in the concentration of transforming growth factor beta (TGF-B), indicating an increase in the production of type I and III collagen [65]. Despite everything described, it should be noted that there are different techniques for the preparation of PRP, thus obtaining different volumes and concentrations of platelets [66,67].

Filardo et al. [68] evaluate the therapeutic effects of multiple PRP injections on the healing of chronic refractory patellar tendinopathy. The results documented were good and stable with the VISA-P score. The ultrasound measurements showed that tendon thickness and neovascularization level gradually decrease over time, despite an initial increase after the injection cycle.

Dallaudière et al. [69] also aimed to assess the efficacy and tolerance of intratendinous injection of PRP to treat tendinopathy. This study included 41 patients had patellar tendinopathy. The average WOMAC scores of 41 patients with patellar tendinopathy improved from 38 to 16 at the 6-week follow-up and more improved (6 scores) at 32-month follow-up. No clinical complication was reported during follow-up. This study demonstrates that the ultrasound-guided injection of PRP allows rapid healing of tendon with good tolerance.

Another study of randomised control trials (RCT) by Dragoo et al. [70] compared a regimen of eccentric exercises combined with either ultrasound-guided PRP injection or ultrasound-guided dry needling alone in the treatment of patellar tendinopathy. The PRP group showed significantly better improvement than the dry needling group in VISA-P score at 12 weeks. However, at 26-week follow-up, the difference between the PRP and dry needling groups dissipated in all assessed scores, such as VISA-P, Tegner, VAS, and short form-12 (SF-12) scores.

Sclerosant injections (polidocanol)

Based on the theory that neovascularization are associated with an underlying mechanism due to overuse in tendinopathies. The randomized, double-blind trial by Alfredson and Öhberg focused on the potential benefit of the sclerosing substance polidocanol on chronic tendinopathies. The VAS pain and the patient's satisfaction at 3 months

of those who were injected, compared with those of whom received injections of local anesthetics only, supported the superiority of the tested treatment, with significant differences in the values recorded ($p < 0.005$) [71].

The use of polidocanol (a vascular sclerosing agent) has been put forth for the treatment of the same [72]. Polidocanol is used to sclerose areas of high intratendinous blood flow, which is sometimes called "neovascularization", visible histopathologically [73] and in vivo by means of high-resolution ultrasound with color doppler.

Some studies have reported effects using polidocanol for patellar tendinopathy, tennis elbow or Achilles tendinopathy [72,74,75].

Studies that associate sclerosing injections and eccentric training have shown a decrease in pain during eccentric training, resulting in complete resolution of pain in the short term Achilles tendinopathy [26].

Zeisig et al. [76] they reported that maintained sclerosis neovascularization in lateral elbow epicondylitis was a good predictor of positive clinical effect at 2 years follow-up.

High-volume image guided injection (HVIGI)

Different methodologies have been described when applying HVIGI. In one study in athletes with achilles tendinopathy, patients were treated with 10 ml of 0.5% bupivacaine hydrochloride injection plus 40 ml saline solution and 25 mg of aprotinin. The HVIGI with aprotinin showed a significant improvement in pain and function in both the short and long term follow up of 12 months [77].

Study groups like those of Chan et al. [78] reported good results with the use of high volume image-guided injections (HVIGI) in the treatment of tendinopathy mainly of the Achilles and patellar tendon, claiming that they significantly reduce pain and improve function.

This intervention uses large volume injections of saline solution, corticosteroids or an anesthetic that make the neovessels stretch, break or occlude. Occlusion or interruption of neovessels supposedly also affects the innervation that it accompanies [79].

Hyaluronic acid (HA)

Possible biological effects of hyaluronic acid (HA) in tendinopathies be related with an anti-inflammatory activity, enhanced cell proliferation, and collagen deposition, besides the lubricating action on the sliding surface of the tendon.

Study groups like those of Petrella et al. [80] determined the efficacy of periarticular HA injections in patients with chronic lateral epicondylitis. Pain, both at rest and after grip testing, was significantly reduced in the study group compared to controls.

Muneta et al. [81] reported good results with the use of HA in the treatment of patellar tendinopathy. After treatment, 94% of patients were rated in excellent in good conditions complained of some degree of limitation.

Injections of the MMP-inhibitor (Aprotinin)

Tendinopathies, are characterized by changes in expression and activity of various metalloproteinase enzymes that degrade the matrix which are consistent with increased proteolytic activity in the degenerate tendons [25].

Aprotinin is a broad spectrum inhibitor of matrix metalloproteinase (MMPs) [82]. It is suggested that by inhibiting the enzymes that break down or degrade tendons, the healing response may be promoted.

In a study by Orchard et al. [83] with 430 patients suffering from patellar and Achilles tendinopathy treated with local injections of aprotinin, the results showed that, at a minimum follow-up of 3 months (range 3-54 months), 76% of patients improved clinically and functionally.

Brown et al. [84] conducted a randomized control trial study (RCT) the use of aprotinin in the treatment of Achilles tendinopathy, 26 patients divided into 2 groups, one group with aprotinin injection and another group with saline (placebo). There were no significant difference scores in VISA-A ($p=0.946$) at 52 weeks of follow-up.

Stem cells

In the last few decades, several emerging strategies including with mesenchymal stem cells (MSC) have been proposed to enhance tendon healing. Stem cells are undifferentiated cells with ability of self-renewing and differentiating in progenitor or precursor cells. The latter are committed cells for a specific cell lineage, but are not able to self-renew [85].

Human MSCs have been isolated from adipose tissue, umbilical cord, placenta, peripheral blood, connective tissues of the dermis and skeletal muscle [86-91].

A stem cell population has been recently identified in human tendons, residing in a unique tendon extracellular matrix (ECM) niche [92].

Tendon stem cells (TSCs) have been described in 2007 by Bi et al. [92]. These stem cells present in mature tendon have multi-differentiation and self-renewal potential [92]. They can differentiate into other cell types, like muscle or fat cells. These cells have been implicated as possible cause of chronic tendinopathy because of the erroneous differentiation into abnormal matrix components causing fatty degeneration and calcification. These cells are still in the preclinical experimentation stage but have great potential for tendon therapy in the future [93].

TCSs could be involved in tendon homeostasis, remodelling, and repair, by ensuring replacement of mature cells lost, or in the pathogenesis of tendinopathy, as this tendon disorder is associated with chondroid and fatty degeneration, and ossification [94].

Since the tendon cell rate is low like its biological turnover, it has recently been proposed that adult stem cells would be good candidates for the regeneration of the tendon [95]. However, the exact role in the healing process of stem cells implanted into the tendon remains uncertain. One possibility is that they differentiate into tenocytes and are involved in healing by producing collagen and remodeling. It has also been suggested that the mononuclear bone marrow stem cells (BM-MNC) can aid in healing by acting as "growth factor pumps" rather than through terminal differentiation [96].

In vitro research has shown encouraging results with the use of stem cells for the treatment of degenerative diseases, like tendinopathy, of the musculoskeletal system [97].

Bone marrow mesenchymal cells (BMSCs) have been shown effective in the management of superficial digital flexor tendon injuries in horses; BMSCs were inoculated in the injured tendons leading to

lower of re-injury rate compared with the re-injury rate obtained with the conventional non cellular based management [98,99].

An experimental study conducted by Lacitignola et al. [100] showed in an in vivo collagenase-induced superficial digital flexor tendinopathy study of horses, that when injected with autologous BMSCs intratendinous it produced a regeneration effect on the tendon.

Also adipose derived stem cells were showed to be effective in the treatment of equine tendinopathies leading to normal horse activity recovery [101].

Obaid et al. [102] perform a RCT study of 40 human patients diagnosed with Achilles tendinosis, a group that was treated with autologous stem cells derived from skin and other serum group saline (placebo). Clinical outcomes were assessed with VAS and VISA-A questionnaire at 3 and 6 months follow-up. Significant improvements in the experimental group compared to the placebo group in VISA-A ($p=0.02$) and VAS ($p<0.001$) scores were found.

In theory, pluripotent stem cells can be isolated and then be integrated into an area of need of the tendon. Once stem cells are at the desired location, either by local signaling or by the addition of exogenous factors, they can lead pluripotent cells to differentiating into the desired cell line [25].

Surgery

Historically, surgery has been proposed as a salvage technique if other treatments fail [103,104], showing similar functional results using an open or arthroscopic technique [105], and the latter with less comorbidity. With surgery, the removal of the degenerated tissue or calcifications in order to promote the tissue response is generally sought.

Lorbach et al. [106] performed a prospective study to evaluate the clinical results of arthroscopic resection of the lower patellar pole in patients with patellar tendinopathy. The main conclusion was that arthroscopic resection of the lower patellar pole as a minimal invasive method to treat patellar tendinopathy provides satisfactory clinical results in knee function and pain reduction with fast recovery and return to sport activities.

Kelly examined the results of arthroscopic tendon debridement with excision of the distal pole of the patella for refractory patellar tendinopathy [107]. He concluded that arthroscopic excision of the distal patellar pole with tendon debridement holds promise for the treatment of refractory patellar tendinopathy.

Shelbourne et al. [108] reported that surgical removal of necrotic tissue, surgical stimulation of remaining tendon, and aggressive rehabilitation after patellar tendonectomy could allow athletes to return to sports. Overall, tendonectomy, surgical tendon stimulation, and aggressive post-operative rehabilitation were found to be a safe, effective way to return high-level athletes to their sports.

Analysis of the surgical treatments is complicated given the differences between both techniques, as well as the heterogeneity of the samples and the different protocols used postoperatively [105].

Discussion

Treatment of tendon injuries is a subject of frequent debate in sports medicine and physiotherapy. Multiple techniques have been described for their treatment and although some of them [46,56,71,106,107].

To date, there is no consensus on the optimal treatment of tendinopathies. It has been suggested that the incomplete understanding of the underlying mechanisms (etiology of the condition), limits the ability to develop effective treatment strategies [108]. Are emerging as the most accepted treatment option, more RCT's are still needed to clearly establish what the therapeutic protocol therapeutic to follow should be.

Doubts have mainly centered on the fact that there are few controlled prospective studies that analyze all aspects of tendinosis, and few studies that investigate the early stages of these processes and their healing mechanisms. The exact mechanism by which tendinopathy develops in humans remains the target of numerous investigations. A variety of degenerative characteristics associated tendinopathies, including accumulation glycosaminoglycan (GAG), calcification and lipid accumulation nerve damage and hyperinnervation, is one of the theories whose publications are scarce, despite its special interest in explaining the possible pathophysiological mechanisms of pain in tendinopathy [109].

In several studies it has been shown that there is a correlation between tendinopathy and hyperinnervation, citing that the production of nerve growth factor (NGF) and the corresponding hyperinnervation could be induced by repetitive ischemic crisis in osteotendinous union [110,111]. This growth of nerve fibers, which causes chronic pain, could be part of a process of abnormal tissue repair, preceded by repetitive micro trauma [112].

Despite its prevalence, the precise pathogenic mechanisms of tendinopathy are not clear and, as a result, current treatments of tendinopathies are largely empirical and not always efficient [17,113]. The continuum model of tendon pathology was proposed to provide a model for the staging of tendon pathology and to assist clinicians in managing this often complex condition. The model presents clinical, histological and imaging evidence for the progression of tendon pathology as a three-stage continuum: reactive tendinopathy, tendon disrepair and degenerative tendinopathy [17].

The use corticosteroids are by far the most utilized treatment in all painful tendinopathy. Da Cruz et al. [114] investigated the role of corticosteroid injections in Achilles tendinopathy, at final follow-up (12 weeks), they were not able to find a significant higher improvement within the intervention group in any of the primary outcomes measured.

Others authors [115] consider that in the absence of an inflammatory process, there is no rational basis for the use of NSAIDs in chronic tendinopathy.

Chen et al. [116] believe that local infiltration of corticosteroids is associated with an increased risk of spontaneous tendon rupture.

A review study conducted by Dean et al. [117] reported that the effects of corticosteroid injection, reduce cell viability, cell proliferation is reduced, degrades collagen, produces higher tendon necrosis, decreases the mechanical properties of the tendon, and it produces significant long-term tissue damage and tendon cells.

One of the clinical effects that eccentric exercises might have in tendinopathy is in pain modulation due to changes in glutamate content or in the central nervous system with increased activation of inhibitory neurons and cortical reorganization [71,118]. There is little evidence that isolated eccentric exercise reduces pain in tendinopathy compared with concentric exercise [119].

It is considered that hypoxia could be responsible for neovascularization in tendinopathies, capillary flow and post-capillary pressure decreased following 12 weeks of eccentric loading [120].

In the treatment of tendinopathy, there is conflicting evidence that eccentric exercises are superior to other load programs [119]. Eccentric work on an inclined plane did not improve functional outcomes when it was done during a competitive season in volleyball [121]. In another study, continuous sporting activity did not compromise clinical outcomes at 12 months, as long as the sport was introduced incrementally ensuring minimal pain during and after loading [122]. Eccentric decline squat training and heavy slow resistance training showed good long-term clinical results, and heavy slow resistance training also resulted in advantages in pathological improvement and increased collagen turnover [37].

Some authors have demonstrated better results with eccentric exercise on corporeal tendinopathies in comparison with enthesopathies [35].

Further studies are needed to assess the unique effects of an eccentric strengthening program. Eccentric loading should be considered in conjunction with the concentric rather than just eccentric loading in Achilles and patellar tendinopathy. Patients with marked muscle weakness may benefit from a program of progressive eccentric-concentric loading [122]. On the other hand, maximal eccentric loading may be best for some groups of patients and permit adaptive changes in the tendon [45].

Despite the fact that the eccentric muscle workout has become the dominant conservative strategy in treating Achilles and patellar tendinopathy, up to 45% of patients do not respond to this treatment [123].

A recent study suggests that sedentary subjects with Achilles tendinopathy may show less promising results with eccentric exercise therapy compared to athletic subjects [124].

In the treatment of chronic lateral epicondylalgia where they were randomly assigned to three groups, one assigned to a stretching program, another to eccentric strengthening and the last to eccentric strengthening with stretching, no significant difference was observed either in the evaluation of strength or the visual analog pain scale [125].

Despite some good results reported with eccentric programmes [123,126], it is still unclear as to the more effective exercise protocol, its frequency, load and dosage.

Despite over 15 years of experience in the use of the EPI® technique and its widespread deployment in sporting clubs around the world, this technique has grown in relative to scientific dissemination in recent years [46].

An experimental study showed that after application of the degenerated tendon EPI® technique, an increase in anti-inflammatory proteins, like PPAR- γ has been observed after treatment with the EPI® technique. These proteins play a key role in the inhibition of expression of proinflammatory molecules secreted by macrophages, such as TNF- α , IL-6 and IL-1 β [127] thus producing in the treated tissue a highly beneficial molecular response during tendinopathy. This, in turn, results in an increase of the expression of VEGF and VEGFR-2, mediators responsible for angiogenesis anti-inflammatory response [128,129].

In another recent study by Sánchez-Ibáñez and co-workers [46] it has been illustrated that when treatment with the US-guided EPI® technique and eccentric exercises in patellar tendinopathy it resulted in extensive improvement in the knee function and a rapid return to the previous level of activity after few sessions. The limitation of this study is the absence of a control group of subjects.

References to the use of the EPI® technique in combination with eccentric exercise can be found in the literature. In those cases the EPI® technique focuses on biological tissue recovery, leaving the functional recovery of tissue biomechanics to eccentric exercise.

The EPI® technique is mainly contraindicated in patients with tumors, articular or systemic infection and bleeding disorders [49].

Regarding the effectiveness of extra-corporeal shock waves therapy (ESWT) for tendinopathy, according to published studies, conclusive results cannot be drawn because the clinical effects are unclear [130,131]. The effectiveness of ESWT may depend on the stage of tendinopathy, it seems more appropriate in degenerative tendinopathy and where conservative treatment has little or no effect [17].

The mechanisms of the therapeutic effect of ESWT in tendinopathy with calcification are also uncertain. It has been proposed that the increased pressure within the therapeutic focus produces a fragmentation and cavitation effect within calcifications and leads to the disruption and disintegration of calcium deposit [132].

Some studies have shown that ESWT is as effective as surgery, but cheaper, and this treatment seems to be a supplement for the treatment of those tendinopathies who are refractory to conventional therapies [133]. In this sense, studies using high-energy ESWT do better in the tendinopathies than those using low-energy ESWT [54]. This is consistent with a recent study that showed ESWT had no effect in athletes with patellar tendinopathy who actively compete [130]. Currently, there is a controversy relative to the utilization of ESWT in the treatment of patellar tendinopathy [134] as well as in Achilles tendinopathy [54].

With the use of the platelet-rich plasma (PRP), the intention is to enhance the natural healing process at the site of injury through the action of growth factors (PDGF, IGF-1, VEGF, bFGF, TGF-β1, EGF, etc.) to promote matrix synthesis and the healing of injured tissue [135]. It should be noted that the delicate balance between these growth factors may have important implications in the control of angiogenesis and fibrosis [135].

Although many studies have been reported positive results using PRP [136,137], others have shown the same effect in comparison with a placebo [138,139]. De Vos et al. [139] found no significant differences between the group of patients with Achilles tendinopathy treated with PRP and the group treated with saline (placebo) to kept under review 24 weeks; these results agree with de Jonge et al. [138].

At the same time, many questions are raised about what the optimal concentration of platelets should be, in which phase of the injury is it better to do infiltration or how it should be prepared [66]. Caution is warranted when comparing different PRP studies, different types of PRP or PRP-derived products have been used, with a variety of platelet concentrations, inclusion of leucocytes, the use of anticoagulant and the use of activating agents.

Through the present research, it is hard to draw a clear conclusion for the effectiveness of PRP treatment on tendinopathy.

PRP injections should be avoided in patients suffering from infection, tumoral disease, coagulation disorders and changes in the number of platelets [135].

The use of polidocanol injection is based on the belief that neovascularizations are associated with the mechanism underlying tendinopathy due to overuse. Although it is unclear whether this is a causal agent in the pathophysiology of tendinopathy [140]. In fact, these "neovessels" may be associated with the ingrowth of nerves in the areas of pathological tendons [141] and it is possible that nerve fibers are the pain generators in chronic tendinopathy [142]. A priori, polidocanol injections may not only sclerose the veins, but may also eliminate the pain nerve fibers [25]. Although polidocanol injections appear to provide pain relief, it is unclear what role they can play in tendon healing in tendinopathy.

Hoksrud et al. [74] reported reduced pain after ultrasound-guided sclerosing in patients with patellar tendinopathy, contradictory results were recently presented in a retrospective study [143] in which sclerosing injections in 48 patients with chronic Achilles tendinopathy revealed less promising results than expected [143]. Even though capillary blood flow may decrease by around 25% [144] some authors say that there is no relationship between changes shown in ultrasound and tendon function after sclerosing treatment.

Willberg et al. [145] compared the clinical effects in patellar tendinopathy after treatment with sclerosing polidocanol injections and arthroscopic shaving. After treatment, the patients treated with arthroscopic shaving had a significantly lower visual analogue score (VAS) score at rest and during activity, and were significantly more satisfied compared with the patients in the sclerosing injection group.

Prospective comparative studies involved small numbers of patients: polidocanol injections were superior to lidocaine injections [75], and similar results were found when compared with patients undergoing mini-open surgery [146].

Although some studies that associate sclerosing injections with eccentric training have shown a decrease in pain [26], further studies to evaluate its safety (possible nerve damage) and effectiveness, to determine the injection protocol (volume/concentration) and its combination with other therapies are needed [141].

Avoid injection of polidocanol in patients who previously had an allergic reaction to polidocanol or diagnosed with a blood clotting disorder. Nor it is recommended in pregnant or latency [141].

While some authors advocate the use of high-volume image guided injection (HVIGI) in treating refractory tendinopathy [77,147]. Preliminary studies have shown that a HVIGI with normal saline, local anaesthetic and corticosteroid can significantly reduce pain and improve short- and long-term function in patients with Achilles tendinopathy [77,78,147] reported results are not conclusive nor homogeneous enough to establish a protocol for use.

HVIGI adverse effects are similar to those of other injection techniques. Caution must be exercised with the administration of the diluted corticosteroid, for possible risk of tendon rupture and should not be injected into the ducts inside and outside the tendon [77].

Hyaluronic acid (HA) is actively secreted by the tendon sheath it is an important component of the synovial fluid, which allows a smooth tendon gliding, and provides nutrition to tendon itself [148]. Moreover, it is an important component of tendon structure, being largely present in extracellular space.

Several studies have been performed to evaluate the efficacy of HA on adhesions, gliding resistance, and tendon healing [149-152].

Despite the promising results of HA injections for treating tendinopathy in most of the studies the joint space has been injected and not into the tendon, and it could be that the modification of the synovial fluid exerts a positive effect on the tendon [153].

Avoid introduction of HA into the tendon and the peritendinous fat to avoid delete rating effects [81].

Aprotinin injections have been shown to provide clinical improvement in tendinopathies, most successful in patients with Achilles tendinopathy or with patellar tendinopathy [55,82]. Also better results have been obtained with aprotinin injections with corticosteroid injections or saline [82].

Moreover, in 7% of cases systemic allergic reactions occurred when aprotinin injections were applied at intervals of 2 to 4 weeks, but if applied every 6 weeks the reactions of systemic allergy was reduced significantly to 0-9%. Positive IgG antibodies against aprotinin patients most at risk of an anaphylactic reaction during treatment with this; therefore the authors recommend that if this type of technique is to be used the necessary equipment to treat anaphylaxis should be present [152].

Brown et al. [84] investigated whether aprotinin could achieve better improvement than the usual rehabilitation protocol adopted to treat Achilles tendinopathy in their RCT. They recorded VISA-A scores, tenderness, satisfaction and other clinical parameters and demonstrated no significant statistical differences.

It has been suggested that the efficacy of stem cells is related to its state of differentiation, i.e., the greater the state of differentiation the more effective will the effect be in the healing of the tissues in which they are implanted [154]. Keeping this statement in mind, it should be remembered that the cells that are better able to differentiate have lower telomere length and therefore a greater degree of aging during wound healing and therefore may not be able to complete the necessary steps in the process of regeneration and produce a useful and sufficient cellular matrix [155].

Another important aspect concerning the use of stem cells is their viability during the inflammatory phase of the tendon [154]. During the inflammatory phase, different types of cytokines, cytotoxic proteins and inflammatory factors are released by necrotic tissue and inflammatory cells reduce the possibilities of viability of stem cells in the host [97,154].

Stem cells are promising candidate for the management of tendinopathies and tendon rupture. However, these cell-based strategies have been investigated only in preclinical studies and the role of stem cells needs to be confirmed. Tendon stem cells have been hypothesized to have a crucial role in the development of calcifying tendinopathy due to the erroneous differentiation of tendon stem cells (TSCs) to chondrocytes or osteoblasts. For this reason it was hypothesized that the re-direction of the differentiation of resident TSCs or supplementation of mesenchymal stem cells (MSCs) programmed for tenogenic differentiation may be appealing targets for the treatment of tendinopathy in the future [156].

The use of stem cells is in the early stage of clinical application in humans. There is only one clinical study performed on human subjects showing that inoculation of bone marrow mononuclear cells (BMMNC) in tendinopathy patellar has good mid-term clinically and

ultrasound results [155]. As demonstrated by these preliminary studies, management of tendinopathies with stem cells is promising even though more clinical studies are needed to validate this treatment approach.

Despite the growing interest in this type of therapy and its expected potential, there are still many open questions to answer in order to implement these techniques in the tendinopathy treatment protocol. Further research is required to identify mechanisms involved in tendon regeneration and in survival, proliferation, and differentiation of stem cells.

Although the results shown by some authors with the surgical treatment of tendinopathy [157-159] showed that surgery did not show advantages over eccentric exercise in their RCT. In addition, the low predictability of the results obtainable through surgery make it such that this technique should be put forward only in selected cases and after other conservative options fail.

It is commonly accepted that surgical treatment must be indicated in motivated patients if carefully followed conservative treatment is unsuccessful after 3-6 months [103,104]. The literature, however, does not clarify which surgical technique is more effective.

Conclusion

In this report, a brief review of treatment approaches of tendinopathy was conducted. Tendinopathy is a condition that causes significant pain and disability in many patients. Currently, the etiology of tendinopathy is still unclear, it is multifactorial, and influenced by intrinsic and extrinsic factors. Tendinopathy often becomes chronic because the exact pathogenesis remains largely unknown. The continuum model of tendon pathology was proposed to provide a model for the staging of tendon pathology. Physicians and physiotherapist have a variety of therapeutic options available to treat tendinopathies but, in each case, there is a lack of evidence supporting their use as the gold standard treatment. Larger randomized controlled trials on the various treatment options and even comparative studies between them are needed to determine the treatment of choice (Gold Standard) for tendinopathies.

Acknowledgement

We are grateful to Julita Cuquerella and David MacManus for your help in editing the manuscript.

Author Contributions

Wrote the first draft of the manuscript: JMS, MEF, JCM, AAD, JSG, JSS. Contributed to the writing of the manuscript: JMS, MEF, JCM, AAD, JSG, JSS. Agree with manuscript results and conclusions: JMS, MEF, JCM, AAD, JSG, JSS. Jointly developed the structure and arguments for the paper: JMS, MEF, JCM, AAD, JSG, JSS. Made critical revisions and approved final version: JMS, MEF, JCM, AAD, JSG, JSS. All authors reviewed and approved the final manuscript.

Disclosures and Ethics

The authors declare that one author has the patent for the EPI devices® and one author is the creator of the EPI® technique.

References

1. Tresoldi I, Oliva F, Benvenuto M, Fantini M, Masuelli L, et al. (2013) Tendon's ultrastructure. *Muscles Ligaments Tendons J* 3: 2-6.
2. Couppé C, Kongsgaard M, Aagaard P, Hansen P, Bojsen-Moller J, et al. (2008) Habitual loading results in tendon hypertrophy and increased stiffness of the human patellar tendon. *J Appl Physiol* (1985) 105: 805-810.
3. Langberg H, Skovgaard D, Asp S, Kjaer M (2000) Time pattern of exercise-induced changes in type I collagen turnover after prolonged endurance exercise in humans. *Calcif Tissue Int* 67: 41-44.
4. Kannus P (1997) Etiology and pathophysiology of chronic tendon disorders in sports. *Scand J Med Sci Sports* 7: 78-85.
5. Kvist M (1994) Achilles tendon injuries in athletes. *Sports Med* 18: 173-201.
6. Maffulli N, Wong J, Almekinders LC (2003) Types and epidemiology of tendinopathy. *Clin Sports Med* 22: 675-692.
7. Edelstein L, Thomas SJ, Soslowky LJ (2011) Rotator cuff tears: what have we learned from animal models? *J Musculoskelet Neuronal Interact* 11: 150-162.
8. Butler DL, Gooch C, Kinneberg KR, Boivin GP, Galloway MT, et al. (2010) The use of mesenchymal stem cells in collagen-based scaffolds for tissue-engineered repair of tendons. *Nat Protoc* 5: 849-863.
9. Hess GW (2010) Achilles tendon rupture: a review of etiology, population, anatomy, risk factors, and injury prevention. *Foot Ankle Spec* 3: 29-32.
10. Scott A, Ashe MC (2006) Common tendinopathies in the upper and lower extremities. *Curr Sports Med Rep* 5: 233-241.
11. Fredberg U, Stengaard-Pedersen K (2008) Chronic tendinopathy tissue pathology, pain mechanisms, and etiology with a special focus on inflammation. *Scand J Med Sci Sports* 18: 3-15.
12. Ferretti A, Papandrea P, Conteduca F (1990) Knee injuries in volleyball. *Sports Med* 10: 132-138.
13. Lian OB, Engebretsen L, Bahr R (2005) Prevalence of jumper's knee among elite athletes from different sports: a cross-sectional study. *Am J Sports Med* 33: 561-567.
14. Alfredson H, Lorentzon R (2002) Chronic tendon pain: no signs of chemical inflammation but high concentrations of the neurotransmitter glutamate. Implications for treatment? *Curr Drug Targets* 3: 43-54.
15. Cook JL, Khan KM, Maffulli N, Purdam C (2000) Overuse tendinosis, not tendinitis part 2: applying the new approach to patellar tendinopathy. *Phys Sportsmed* 28: 31-46.
16. Warden SJ, Kiss ZS, Malara FA, Ooi AB, Cook JL, et al. (2007) Comparative accuracy of magnetic resonance imaging and ultrasonography in confirming clinically diagnosed patellar tendinopathy. *Am J Sports Med* 35: 427-436.
17. Cook JL, Purdam CR (2009) Is tendon pathology a continuum? A pathology model to explain the clinical presentation of load-induced tendinopathy. *Br J Sports Med* 43: 409-416.
18. Maffulli N, Testa V, Capasso G, Ewen SW, Sullo A, et al. (2004) Similar histopathological picture in males with Achilles and patellar tendinopathy. *Med Sci Sports Exerc* 36: 1470-1475.
19. Kader D, Saxena A, Movin T, Maffulli N (2002) Achilles tendinopathy: some aspects of basic science and clinical management. *Br J Sports Med* 36: 239-249.
20. Backman LJ, Andersson G, Wennstig G, Forsgren S, Danielson P (2011) Endogenous substance P production in the Achilles tendon increases with loading in an in vivo model of tendinopathy-peptidergic elevation preceding tendinosis-like tissue changes. *J Musculoskelet Neuronal Interact* 11: 133-140.
21. Alfredson H, Forsgren S, Thorsen K, Fahlstrom M, Johansson H, et al. (2001) Glutamate NMDAR1 receptors localised to nerves in human Achilles tendons: Implications for treatment? *Knee Surg Sports Traumatol Arthrosc* 9: 123-126.
22. Molloy TJ, Kemp MW, Wang Y, Murrell GA (2006) Microarray analysis of the tendinopathic rat supraspinatus tendon: glutamate signaling and its potential role in tendon degeneration. *J Appl Physiol* (1985) 101: 1702-1709.
23. Cook JL, Khan KM (2001) What is the most appropriate treatment for patellar tendinopathy? *Br J Sports Med* 35: 291-294.
24. Peers KH, Lysens RJ (2005) Patellar tendinopathy in athletes: current diagnostic and therapeutic recommendations. *Sports Med* 35: 71-87.
25. Andres BM, Murrell GA (2008) Treatment of tendinopathy: what works, what does not, and what is on the horizon. *Clin Orthop Relat Res* 466: 1539-1554.
26. Alfredson H (2005) Conservative management of Achilles tendinopathy: new ideas. *Foot Ankle Clin* 10: 321-329.
27. Fournier PE, Rappoport G (2005) [Tendinopathy: physiopathology and conservative treatment]. *Rev Med Suisse* 1: 1840-1842, 1845-1846.
28. Glaser T, Poddar S, Tweed B, Webb CW (2008) Clinical inquiries. What's the best way to treat Achilles tendonopathy? *J Fam Pract* 57: 261-263.
29. Tsai WC, Hsu CC, Chou SW, Chung CY, Chen J, et al. (2007) Effects of celecoxib on migration, proliferation and collagen expression of tendon cells. *Connect Tissue Res* 48: 46-51.
30. Riley GP, Cox M, Harrall RL, Clements S, Hazleman BL (2001) Inhibition of tendon cell proliferation and matrix glycosaminoglycan synthesis by non-steroidal anti-inflammatory drugs in vitro. *J Hand Surg Br* 26: 224-228.
31. Christensen B, Dandanell S, Kjaer M, Langberg H (2011) Effect of anti-inflammatory medication on the running-induced rise in patella tendon collagen synthesis in humans. *J Appl Physiol* (1985) 110: 137-141.
32. Järvinen TA, Järvinen TL, Kääriäinen M, Aärimaa V, Vaittinen S, et al. (2007) Muscle injuries: optimising recovery. *Best Pract Res Clin Rheumatol* 21: 317-331.
33. Coombes BK, Bisset L, Brooks P, Khan A, Vicenzino B (2013) Effect of corticosteroid injection, physiotherapy, or both on clinical outcomes in patients with unilateral lateral epicondylalgia: a randomized controlled trial. *JAMA* 309: 461-469.
34. Maffulli N, Papalia R, D'Adamio S, Diaz Balzani L, Denaro V (2015) Pharmacological interventions for the treatment of Achilles tendinopathy: a systematic review of randomized controlled trials. *Br Med Bull* 113: 101-115.
35. Magnusson RA, Dunn WR, Thomson AB (2009) Nonoperative treatment of midportion Achilles tendinopathy: a systematic review. *Clin J Sport Med* 19: 54-64.
36. Coombes BK, Bisset L, Vicenzino B (2010) Efficacy and safety of corticosteroid injections and other injections for management of tendinopathy: a systematic review of randomised controlled trials. *Lancet* 376: 1751-1767.
37. Kongsgaard M, Kovanen V, Aagaard P, Doessing S, Hansen P, et al. (2009) Corticosteroid injections, eccentric decline squat training and heavy slow resistance training in patellar tendinopathy. *Scand J Med Sci Sports* 19: 790-802.
38. Olesen JL, Heinemeier KM, Gemmer C, Kjaer M, Flyvbjerg A, et al. (2007) Exercise-dependent IGF-I, IGF1Ps, and type I collagen changes in human peritendinous connective tissue determined by microdialysis. *J Appl Physiol* (1985) 102: 214-220.
39. Alfredson H, Pietilä T, Jonsson P, Lorentzon R (1998) Heavy-load eccentric calf muscle training for the treatment of chronic Achilles tendinosis. *Am J Sports Med* 26: 360-366.
40. Mafi N, Lorentzon R, Alfredson H (2001) Superior short-term results with eccentric calf muscle training compared to concentric training in a randomized prospective multicenter study on patients with chronic Achilles tendinosis. *Knee Surg Sports Traumatol Arthrosc* 9: 42-47.
41. Magnusson SP, Langberg H, Kjaer M (2010) The pathogenesis of tendinopathy: balancing the response to loading. *Nat Rev Rheumatol* 6: 262-268.

42. Ohberg L, Lorentzon R, Alfredson H (2004) Eccentric training in patients with chronic achilles tendinosis: normalised tendon structure and decreased thickness at follow up. *Br J Sports Med* 38: 8-11.
43. Visnes H, Bahr R (2007) The evolution of eccentric training as treatment for patellar tendinopathy (jumper's knee): a critical review of exercise programmes. *Br J Sports Med* 41: 217-223.
44. Silbernagel KG, Thomeé R, Thomeé P, Karlsson J (2001) Eccentric overload training for patients with chronic Achilles tendon pain--a randomised controlled study with reliability testing of the evaluation methods. *Scand J Med Sci Sports* 11: 197-206.
45. Romero-Rodriguez D, Gual G, Tesch PA (2011) Efficacy of an inertial resistance training paradigm in the treatment of patellar tendinopathy in athletes: a case-series study. *Phys Ther Sport* 12: 43-48.
46. Abat F, Gelber P, Polidori F, Monllau JC, Sánchez-Ibáñez JM (2015) Clinical results after ultrasound-guided intratissue percutaneous electrolysis (EPI®) and eccentric exercise in the treatment of patellar tendinopathy. *Knee Surg Sports Traumatol Arthrosc* 23: 1046-1052.
47. Abat F, Diesel WJ, Gelber PE, Polidori F, Monllau JC, et al. (2014) Effectiveness of the Intratissue Percutaneous Electrolysis (EPI®) technique and isoinertial eccentric exercise in the treatment of patellar tendinopathy at two years follow-up. *Muscles Ligaments Tendons J* 4: 188-193.
48. Abat F, Valles SL, Gelber PE, Polidori F, Stitik TP, et al. (2014) Molecular repair mechanisms using the Intratissue Percutaneous Electrolysis technique in patellar tendonitis. *Rev Esp Cir Ortop Traumatol* 58: 201-205.
49. Sánchez-Ibáñez JM. Clinical evolution in the chronic patellar enthesopathy treatment by EPI® Technique guided-ultrasound - Study of several cases in sports population. [PhD. Thesis], Universidad de León. León. Spain. 2013.
50. Sanchez-Ibáñez JM, Colmena C, Benabent J, Garcia-Herreros S, Valles SL (2013) New Technique in Tendon Sport Recovery. Percutaneous Electrolysis Intratissue (EPI®). *Int J Phys Med Rehabil* 1: 113.
51. Abat F, Valles SL, Gelber PE, Polidori F, Jorda A, et al. (2015) An experimental study of muscular injury repair in a mouse model of notexin-induced lesion with EPI® technique. *BMC Sports Sci Med Rehabil* 7: 7.
52. Skutek M, van Griensven M, Zeichen J, Brauer N, Bosch U (2001) Cyclic mechanical stretching enhances secretion of Interleukin 6 in human tendon fibroblasts. *Knee Surg Sports Traumatol Arthrosc* 9: 322-326.
53. Tsuzaki M, Bynum D, Almekinders L, Yang X, Faber J, et al. (2003) ATP modulates load-inducible IL-1beta, COX 2, and MMP-3 gene expression in human tendon cells. *J Cell Biochem* 89: 556-562.
54. Furia JP (2006) High-energy extracorporeal shock wave therapy as a treatment for insertional Achilles tendinopathy. *Am J Sports Med* 34: 733-740.
55. Hennessy MS, Molloy AP, Sturdee SW (2007) Noninsertional Achilles tendinopathy. *Foot Ankle Clin* 12: 617-641, vi-vii.
56. Rompe JD, Maffulli N (2007) Repetitive shock wave therapy for lateral elbow tendinopathy (tennis elbow): a systematic and qualitative analysis. *Br Med Bull* 83: 355-378.
57. Chao YH, Tsuang YH, Sun JS, Chen LT, Chiang YF, et al. (2008) Effects of shock waves on tenocyte proliferation and extracellular matrix metabolism. *Ultrasound Med Biol* 34: 841-852.
58. van der Worp H, van den Akker-Scheek I, van Schie H, Zwerver J (2013) ESWT for tendinopathy: technology and clinical implications. *Knee Surg Sports Traumatol Arthrosc* 21: 1451-1458.
59. Peers KHE (2003) Extracorporeal shock wave therapy in chronic achilles and patellar tendinopathy. Thesis, KU Leuven (ISBN: 9058673049).
60. Rompe JD, Furia J, Maffulli N (2009) Eccentric loading versus eccentric loading plus shock-wave treatment for midportion achilles tendinopathy: a randomized controlled trial. *Am J Sports Med* 37: 463-470.
61. Middleton KK, Barro V, Muller B, Terada S, Fu FH (2012) Evaluation of the effects of platelet-rich plasma (PRP) therapy involved in the healing of sports-related soft tissue injuries. *Iowa Orthop J* 32: 150-163.
62. Foster TE, Puskas BL, Mandelbaum BR, Gerhardt MB, Rodeo SA (2009) Platelet-rich plasma: from basic science to clinical applications. *Am J Sports Med* 37: 2259-2272.
63. Kaux JF, Degrave N, Crielaard JM (2007) Platelet rich plasma : traitement des tendinopathies chroniques? *Revue de la littérature. Journal de Traumatologie du Sport* 24: 99-102.
64. Kajikawa Y, Morihara T, Sakamoto H, Matsuda K, Oshima Y, et al. (2008) Platelet-rich plasma enhances the initial mobilization of circulation-derived cells for tendon healing. *J Cell Physiol* 215: 837-845.
65. Klein MB, Yalamanchi N, Pham H, Longaker MT, Chang J (2002) Flexor tendon healing in vitro: effects of TGF-beta on tendon cell collagen production. *J Hand Surg Am* 27: 615-620.
66. Leitner GC, Gruber R, Neumüller J, Wagner A, Kloimstein P, et al. (2006) Platelet content and growth factor release in platelet-rich plasma: a comparison of four different systems. *Vox Sang* 91: 135-139.
67. Kaux JF, Le Goff C, Seidel L, Péters P, Gothot A, et al. (2011) [Comparative study of five techniques of preparation of platelet-rich plasma]. *Pathol Biol (Paris)* 59: 157-160.
68. Filardo G, Kon E, Di Matteo B, Pelotti P, Di Martino A, et al. (2013) Platelet-rich plasma for the treatment of patellar tendinopathy: clinical and imaging findings at medium-term follow-up. *Int Orthop* 37: 1583-1589.
69. Dallaudière B, Pesquer L, Meyer P, Silvestre A, Perozziello A, et al. (2014) Intratendinous injection of platelet-rich plasma under US guidance to treat tendinopathy: a long-term pilot study. *J Vasc Interv Radiol* 25: 717-723.
70. Dragoo JL, Wasterlain AS, Braun HJ, Nead KT (2014) Platelet-rich plasma as a treatment for patellar tendinopathy: a double-blind, randomized controlled trial. *Am J Sports Med* 42: 610-618.
71. Alfredson H, Ohberg L, Forsgren S (2003) Is vasculo-neural ingrowth the cause of pain in chronic Achilles tendinosis? An investigation using ultrasonography and colour Doppler, immunohistochemistry, and diagnostic injections. *Knee Surg Sports Traumatol Arthrosc* 11: 334-338.
72. Kraushaar BS, Nirschl RP (1999) Tendinosis of the elbow (tennis elbow). Clinical features and findings of histological, immunohistochemical, and electron microscopy studies. *J Bone Joint Surg Am* 81: 259-278.
73. Alfredson H, Ohberg L (2005) Neovascularisation in chronic painful patellar tendinosis-promising results after sclerosing neovessels outside the tendon challenge the need for surgery. *Knee Surg Sports Traumatol Arthrosc* 13: 74-80.
74. Hoksrud A, Ohberg L, Alfredson H, Bahr R (2006) Ultrasound-guided sclerosis of neovessels in painful chronic patellar tendinopathy: a randomized controlled trial. *Am J Sports Med* 34: 1738-1746.
75. Alfredson H, Ohberg L (2015) Sclerosing injections to areas of neovascularization reduces pain in chronic Achilles tendinopathy: a double-blind randomised trial. *Knee Surg Sports Traumatol Arthrosc* 13: 338-344.
76. Zeisig E, Fahlström M, Ohberg L, Alfredson H (2010) A two-year sonographic follow-up after intratendinous injection therapy in patients with tennis elbow. *Br J Sports Med* 44: 584-587.
77. Maffulli N, Spiezia F, Longo UG, Denaro V, Maffulli GD (2013) High volume image guided injections for the management of chronic tendinopathy of the main body of the Achilles tendon. *Phys Ther Sport* 14: 163-167.
78. Chan O, O'Dowd D, Padhiar N, Morrissey D, King J, et al. (2008) High volume image guided injections in chronic Achilles tendinopathy. *Disabil Rehabil* 30: 1697-1708.
79. Loppini M, Maffulli N (2012) Conservative management of tendinopathy: an evidence-based approach. *Muscles Ligaments Tendons J* 1: 134-137.
80. Petrella RJ, Cogliano A, Decaria J, Mohamed N, Lee R (2010) Management of Tennis Elbow with sodium hyaluronate periarticular injections. *Sports Med Arthrosc Rehabil Ther Technol* 2: 4.

81. Muneta T, Koga H, Ju YJ, Mochizuki T, Sekiya I (2012) Hyaluronan injection therapy for athletic patients with patellar tendinopathy. *J Orthop Sci* 17: 425-431.
82. Orchard J, Massey A, Brown R, Cardon-Dunbar A, Hofmann J (2008) Successful management of tendinopathy with injections of the MMP-inhibitor aprotinin. *Clin Orthop Relat Res* 466: 1625-1632.
83. Orchard J, Massey A, Brown R, Cardon-Dunbar A, Hofmann J (2008) Successful management of tendinopathy with injections of the MMP-inhibitor aprotinin. *Clin Orthop Relat Res* 466: 1625-1632.
84. Brown R, Orchard J, Kinchington M, Hooper A, Nalder G (2006) Aprotinin in the management of Achilles tendinopathy: a randomised controlled trial. *Br J Sports Med* 40: 275-279.
85. Zipori D (2005) The stem state: plasticity is essential, whereas self-renewal and hierarchy are optional. *Stem Cells* 23: 719-726.
86. Zuk PA, Zhu M, Mizuno H, Huang J, Futrell JW, et al. (2001) Multilineage cells from human adipose tissue: implications for cell-based therapies. *Tissue Eng* 7: 211-228.
87. Bieback K, Kern S, Klüter H, Eichler H (2004) Critical parameters for the isolation of mesenchymal stem cells from umbilical cord blood. *Stem Cells* 22: 625-634.
88. Goodwin HS, Bicknese AR, Chien SN, Bogucki BD, Quinn CO, et al. (2001) Multilineage differentiation activity by cells isolated from umbilical cord blood: expression of bone, fat, and neural markers. *Biol Blood Marrow Transplant* 7: 581-588.
89. Rus Ciucă D, Sorițău O, Sușman S, Pop VI, Mișu CM (2011) Isolation and characterization of chorionic mesenchymal stem cells from the placenta. *Rom J Morphol Embryol* 52: 803-808.
90. Kuznetsov SA, Mankani MH, Gronthos S, Satomura K, Bianco P, et al. (2001) Circulating skeletal stem cells. *J Cell Biol* 153: 1133-1140.
91. Jiang Y, Vaessen B, Lenvik T, Blackstad M, Reyes M, et al. (2002) Multipotent progenitor cells can be isolated from postnatal murine bone marrow, muscle, and brain. *Exp Hematol* 30: 896-904.
92. Bi Y, Ehrlichou D, Kilts TM, Inkson CA, Embree MC, et al. (2007) Identification of tendon stem/progenitor cells and the role of the extracellular matrix in their niche. *Nat Med* 13: 1219-1227.
93. Zhang J, Wang JH (2010) Mechanobiological response of tendon stem cells: implications of tendon homeostasis and pathogenesis of tendinopathy. *J Orthop Res* 28: 639-643.
94. Longo UG, Franceschi F, Ruzzini L, Rabitti C, Morini S, et al. (2007) Light microscopic histology of supraspinatus tendon ruptures. *Knee Surg Sports Traumatol Arthrosc* 15: 1390-1394.
95. Chong AK, Ang AD, Gohetal JC (2007) Bone marrow-derived mesenchymal stem cells influence early tendon-healing in a rabbit achilles tendon model. *J Bone Joint Surg Am* 89: 74-81.
96. Ouyang HW, Goh JC, Lee EH (2004) Viability of allogeneic bone marrow stromal cells following local delivery into patella tendon in rabbit model. *Cell Transplant* 13: 649-657.
97. Sharma P, Maffulli N (2008) Tendinopathy and tendon injury: the future. *Disabil Rehabil* 30: 1733-1745.
98. Smith RK (2008) Mesenchymal stem cell therapy for equine tendinopathy. *Disabil Rehabil* 30: 1752-1758.
99. Godwin EE, Young NJ, Dudhia J, Beamish IC, Smith RK (2012) Implantation of bone marrow-derived mesenchymal stem cells demonstrates improved outcome in horses with overstrain injury of the superficial digital flexor tendon. *Equine Vet J* 44: 25-32.
100. Lacitignola L, Crovace A, Rossi G, Francioso E (2008) Cell therapy for tendinitis, experimental and clinical report. *Vet Res Commun* 32: S33-38.
101. Del Bue M, Riccò S, Ramoni R, Conti V, Gnudi G, et al. (2008) Equine adipose-tissue derived mesenchymal stem cells and platelet concentrates: their association in vitro and in vivo. *Vet Res Commun* 32: S51-55.
102. Obaid H, Clarke A, Rosenfeld P, Leach C, Connell D (2012) Skin-derived fibroblasts for the treatment of refractory Achilles tendinosis: preliminary short-term results. *J Bone Joint Surg* 94: 193-200.
103. Ferretti A, Conteduca F, Camerucci E, Morelli F (2002) Patellar tendinosis: a follow-up study of surgical treatment. *J Bone Joint Surg Am* 84A: 2179-85.
104. Pascarella A, Alam M, Pascarella F, Latte C, Di Salvatore MG, et al. (2011) Arthroscopic management of chronic patellar tendinopathy. *Am J Sports Med* 39: 1975-1983.
105. Rodríguez-Merchan EC (2013) The treatment of patellar tendinopathy. *J Orthop Traumatol* 14: 77-81.
106. Lorbach O, Diamantopoulos A, Paessler HH (2008) Arthroscopic resection of the lower patellar pole in patients with chronic patellar tendinosis. *Arthroscopy* 24: 167-173.
107. Kelly JD 4th (2009) Arthroscopic excision of distal pole of patella for refractory patellar tendinitis. *Orthopedics* 32: 504.
108. Shelbourne KD, Henne TD, Gray T (2006) Recalcitrant patellar tendinosis in elite athletes: surgical treatment in conjunction with aggressive postoperative rehabilitation. *Am J Sports Med* 34: 1141-1146.
109. Riley G (2004) The pathogenesis of tendinopathy. A molecular perspective. *Rheumatology (Oxford)* 43: 131-142.
110. Danielson P, Andersson G, Alfredson H, Forsgren S (2008) Marked sympathetic component in the perivascular innervation of the dorsal paratendinous tissue of the patellar tendon in arthroscopically treated tendinosis patients. *Knee Surg Sports Traumatol Arthrosc* 16: 621-626.
111. Bagege J, Lorentzon R, Alfredson H, Forsgren S (2009) Unexpected presence of the neurotrophins NGF and BDNF and the neurotrophin receptor p75 in the tendon cells of the human Achilles tendon. *Histol Histopathol* 24: 839-848.
112. Danielson P, Alfredson H, Forsgren S (2007) In situ hybridization studies confirming recent findings of the existence of a local nonneuronal catecholamine production in human patellar tendinosis. *Microsc Res Tech* 70: 908-911.
113. Wang JH, Iosifidis MI, Fu FH (2006) Biomechanical basis for tendinopathy. *Clin Orthop Relat Res* 443: 320-332.
114. DaCruz DJ, Geeson M, Allen MJ, Phair I (1988) Achilles paratendinitis: an evaluation of steroid injection. *Br J Sports Med* 22: 64-65.
115. Magra M, Maffulli N (2006) Nonsteroidal antiinflammatory drugs in tendinopathy: friend or foe. *Clin J Sport Med* 16: 1-3.
116. Chen SK, Lu CC, Chou PH, Guo LY, Wu WL (2009) Patellar tendon ruptures in weight lifters after local steroid injections. *Arch Orthop Trauma Surg* 129: 369-372.
117. Dean BJ, Lostis E, Oakley T, Rombach I, Morrey ME, et al. (2014) The risks and benefits of glucocorticoid treatment for tendinopathy: a systematic review of the effects of local glucocorticoid on tendon. *Semin Arthritis Rheum* 43: 570-576.
118. Wand BM, O'Connell NE (2008) Chronic non-specific low back pain - sub-groups or a single mechanism? *BMC Musculoskelet Disord* 9: 11.
119. Jonsson P, Alfredson H (2005) Superior results with eccentric compared to concentric quadriceps training in patients with jumper's knee: a prospective randomised study. *Br J Sports Med* 39: 847-850.
120. Knobloch K, Kraemer R, Jagodzinski M, Zeichen J, Meller R, et al. (2007) Eccentric training decreases paratendon capillary blood flow and preserves paratendon oxygen saturation in chronic achilles tendinopathy. *J Orthop Sports Phys Ther* 37: 269-276.
121. Visnes H, Hoksrud A, Cook J, Bahr R (2005) No effect of eccentric training on jumper's knee in volleyball players during the competitive season: a randomized clinical trial. *Clin J Sport Med* 15: 227-234.
122. Silbernagel KG, Thomeé R, Eriksson BI, Karlsson J (2007) Continued sports activity, using a pain-monitoring model, during rehabilitation in patients with Achilles tendinopathy: a randomized controlled study. *Am J Sports Med* 35: 897-906.
123. Malliaras P, Barton CJ, Reeves ND, Langberg H (2013) Achilles and patellar tendinopathy loading programmes : a systematic review comparing clinical outcomes and identifying potential mechanisms for effectiveness. *Sports Med* 43: 267-286.
124. Sayana MK, Maffulli N (2007) Eccentric calf muscle training in non-athletic patients with Achilles tendinopathy. *J Sci Med Sport* 10: 52-58.

125. Martinez-Silvestrini JA, Newcomer KL, Gay RE, Schaefer MP, Kortebein P, et al. (2005) Chronic lateral epicondylitis: comparative effectiveness of a home exercise program including stretching alone versus stretching supplemented with eccentric or concentric strengthening. *J Hand Ther* 18: 411-419.
126. Silbernagel KG, Brorsson A, Lundberg M (2011) The majority of patients with Achilles tendinopathy recover fully when treated with exercise alone: a 5-year follow-up. *Am J Sports Med* 39: 607-613.
127. Jiang C, Ting AT, Seed B (1998) PPAR-gamma agonists inhibit production of monocyte inflammatory cytokines. *Nature* 391: 82-86.
128. Sahin H, Tholema N, Petersen W, Raschke MJ, Stange R (2012) Impaired biomechanical properties correlate with neoangiogenesis as well as VEGF and MMP-3 expression during rat patellar tendon healing. *J Orthop Res* 30: 1952-1957.
129. Nakama LH, King KB, Abrahamsson S, Rempel DM (2006) VEGF, VEGFR-1, and CTGF cell densities in tendon are increased with cyclical loading: An in vivo tendinopathy model. *J Orthop Res* 24: 393-400.
130. Zwerver J, Hartgens F, Verhagen E, van der Worp H, van den Akker-Scheek I, et al. (2011) No effect of extracorporeal shockwave therapy on patellar tendinopathy in jumping athletes during the competitive season: a randomized clinical trial. *Am J Sports Med* 39: 1191-1199.
131. Rees JD, Maffulli N, Cook J (2009) Management of tendinopathy. *Am J Sports Med* 37: 1855-1867.
132. Mouzopoulos G, Stamatakos M, Mouzopoulos D, Tzurbakis M (2007) Extracorporeal shock wave treatment for shoulder calcific tendonitis: a systematic review. *Skeletal Radiol* 36: 803-811.
133. Rasmussen S, Christensen M, Mathiesen I, Simonson O (2008) Shockwave therapy for chronic Achilles tendinopathy: a double-blind, randomized clinical trial of efficacy. *Acta Orthop* 79: 249-256.
134. Vulpiani MC, Vetrano M, Savoia V, Di Pangrazio E, Trischitta D, et al. (2007) Jumper's knee treatment with extracorporeal shock wave therapy: a long-term follow-up observational study. *J Sports Med Phys Fitness* 47: 323-328.
135. Anitua E, Sanchez M, Nurden AT, Zalduendo M, de la Fuente M, et al. (2007) Reciprocal actions of platelet-secreted TGF-beta1 on the production of VEGF and HGF by human tendon cells. *Plast Reconstr Surg* 119: 950-959.
136. Filardo G, Kon E, Della Villa S, Vincentelli F, Fornasari PM, et al. (2010) Use of platelet-rich plasma for the treatment of refractory jumper's knee. *Int Orthop* 34: 909-915.
137. Peerbooms JC, Sluimer J, Bruijn DJ, Gosens T (2010) Positive effect of an autologous platelet concentrate in lateral epicondylitis in a double-blind randomized controlled trial: platelet-rich plasma versus corticosteroid injection with a 1-year follow-up. *Am J Sports Med* 38: 255-262.
138. de Jonge S, de Vos RJ, Weir A, van Schie HT, Bierma-Zeinstra SM, et al. (2011) One-year follow-up of platelet-rich plasma treatment in chronic Achilles tendinopathy: a double-blind randomized placebo-controlled trial. *Am J Sports Med* 39: 1623-1629.
139. de Vos RJ, Weir A, van Schie HT, Bierma-Zeinstra SM, Verhaar JA, et al. (2010) Platelet-rich plasma injection for chronic Achilles tendinopathy: a randomized controlled trial. *JAMA* 303: 144-149.
140. Scott A, Cook JL, Hart DA, Walker DC, Duronio V, et al. (2007) Tenocyte responses to mechanical loading in vivo: a role for local insulin-like growth factor 1 signaling in early tendinosis in rats. *Arthritis Rheum* 56: 871-881.
141. Rabago D, Best TM, Zgierska AE, Zeisig E, Ryan M, et al. (2009) A systematic review of four injection therapies for lateral epicondylitis: prolotherapy, polidocanol, whole blood and platelet rich plasma. *British Journal of Sports Medicine* 43: 471-481.
142. Scott A, Lian Ø, Bahr R, Hart DA, Duronio V (2008) VEGF expression in patellar tendinopathy: a preliminary study. *Clin Orthop Relat Res* 466: 1598-1604.
143. van Sterkenburg MN, de Jonge MC, Siersevelt IN, van Dijk CN (2010) Less promising results with sclerosing ethoxysclerol injections for midportion achilles tendinopathy: a retrospective study. *Am J Sports Med* 38: 2226-2232.
144. Knobloch K, Spies M, Busch KH, Vogt PM (2007) Sclerosing therapy and eccentric training in flexor carpi radialis tendinopathy in a tennis player. *Br J Sports Med* 41: 920-921.
145. Willberg L, Sunding K, Forssblad M, Fahlström M, Alfredson H (2011) Sclerosing polidocanol injections or arthroscopic shaving to treat patellar tendinopathy/jumper's knee? A randomised controlled study. *Br J Sports Med* 45: 411-415.
146. Alfredson H, Ohberg L, Zeisig E, Lorentzon R (2007) Treatment of midportion Achilles tendinosis: similar clinical results with US and CD-guided surgery outside the tendon and sclerosing polidocanol injections. *Knee Surg Sports Traumatol Arthrosc* 15: 1504-1509.
147. Humphrey J, Chan O, Crisp T, Padhiar N, Morrissey D, et al. (2010) The short-term effects of high volume image guided injections in resistant non-insertional Achilles tendinopathy. *J Sci Med Sport* 13: 295-298.
148. Hagberg L, Heinegard D and K. Ohlsson K (1992) The contents of macromolecule solutes in flexor tendon sheath fluid and their relation to synovial fluid; A quantitative analysis. *J Hand Surg Br* 17: 167-171.
149. Kolodzinskiy MN, Zhao C, Sun YL, An KN, Thoreson AR, et al. (2013) The effects of hylan g-f 20 surface modification on gliding of extrasynovial canine tendon grafts in vitro. *J Hand Surg Am* 38: 231-236.
150. Momose T, Amadio PC, Zobitz ME, Zhao C, An KN (2002) Effect of paratenon and repetitive motion on the gliding resistance of tendon of extrasynovial origin. *Clin Anat* 15: 199-205.
151. Işık S, Oztürk S, Gürses S, Yetmez M, Güler MM, et al. (1999) Prevention of restrictive adhesions in primary tendon repair by HA-membrane: experimental research in chickens. *Br J Plast Surg* 52: 373-379.
152. Liu Y, Skardal A, Shu XZ, Prestwich GD (2008) Prevention of peritendinous adhesions using a hyaluronan-derived hydrogel film following partial-thickness flexor tendon injury. *J Orthop Res* 26: 562-569.
153. Abate M, Schiavone CI, Salini VI (2014) The use of hyaluronic acid after tendon surgery and in tendinopathies. *Biomed Res Int* 2014: 783632.
154. Moshiri A, Oryan A, Meimandi-Parizi A (2013) Role of stem cell therapy in orthopaedic tissue engineering and regenerative medicine: a comprehensive review of the literature from basic to clinical application. *Hard Tissue* 2: 31.
155. Pascual-Garrido C, Rolón A, Makino A (2012) Treatment of chronic patellar tendinopathy with autologous bone marrow stem cells: a 5-year-followup. *Stem Cells Int* 2012: 953510.
156. Rui YF, Lui PP, Chan LS, Chan KM, Fu SC, et al. (2011) Does erroneous differentiation of tendon-derived stem cells contribute to the pathogenesis of calcifying tendinopathy? *Chin Med J (Engl)* 124: 606-610.
157. Cucurulo T, Louis ML, Thauinat M, Franceschi JP (2009) Surgical treatment of patellar tendinopathy in athletes. A retrospective multicentric study. *Orthop Traumatol Surg Res* 95: S78-84.
158. Bahr R, Fossan B, Løken S, Engebretsen L (2006) Surgical treatment compared with eccentric training for patellar tendinopathy (Jumper's Knee). A randomized, controlled trial. *J Bone Joint Surg Am* 88: 1689-1698.
159. Santander J, Zarba E, Iraporda H, Puleo S (2012) Can arthroscopically assisted treatment of chronic patellar tendinopathy reduce pain and restore function? *Clin Orthop Relat Res* 470: 993-997.