

## Ultrasound-Guided EPI® Technique and Eccentric Exercise, New Treatment for Achilles and Patellar Tendinopathy Focused on the Region-Specific of the Tendon

Jose Manuel Sánchez-Ibáñez<sup>1\*</sup>, Maria Elisa Fernández<sup>1</sup>, Carlos Moreno<sup>2</sup>, Daniel Martí<sup>3</sup> and Pedro Belón<sup>4</sup>

<sup>1</sup>Department of Sports Rehabilitation, CEREDE Sports Orthopaedics Medicine & Rehabilitation Clinic, Barcelona, Spain

<sup>2</sup>Department of Sports Medicine and Rehabilitation, Udinese Calcio FC, Udine, Italy

<sup>3</sup>Department of Sports Medicine and Rehabilitation, Tottenham Hotspur FC, Hotspur Way, Enfield, Middlesex, UK

<sup>4</sup>Department of Physical Therapy, Clinica CEMTRO, Madrid, Spain

### Abstract

Treatment of tendon injuries is a subject of frequent debate in sports medicine and physiotherapy. Achilles and patellar tendinopathy is a common, painful, overuse disorder, and is associated with a failure of the tendon repair process they have a low potential for healing with the usual techniques.

Therefore, new treatments for tendinopathies drawn from the existing literature as well as from their own experience dealing with this condition to deal with this delicate pathology have been developed over recent past decades.

This brief review aims to update recent information on the treatment with the ultrasound-guided EPI® technique and eccentric exercise in Achilles and patellar tendinopathy resulted in a great improvement in function and a rapid return to the previous level of activity.

**Keywords:** Tendinopathy; EPI technique; Eccentric exercise therapy

### Introduction

The Achilles tendon and patellar tendon are most affected, in both elite and recreational athletes, in sports that heavily load the lower extremities [1]. It is tendons play an essential role in the musculoskeletal system by transferring the tensile loads from muscle to bone so as to enable joint motion and stabilization [2]. Despite this ability to adapt to physiological loads tendinopathies it represents a clinical problem which affects both professional and recreational athletes as well as people involved in repetitive work [3,4]. Tendinopathies overuse represents 30 to 50 % of all sports injuries and result in a significant amount of morbidity and spending health care [5], it is estimated that they could cost the United States health system some 30 billion dollars, annually [6].

The etiology de la Achilles and patellar tendinopathy includes lifestyle, loading pattern, biological variables (genetics, age, sex) as well as different pharmacological agents [7].

Achilles tendinopathy is more prevalent in the lower extremity, with a frequency of 5.9% in sedentary and about 50 % for endurance athletes [8,9]. Patellar tendinopathy is most common involvement in the knee and its prevalence has been reported to be 44.6% in elite volleyball players [10] and 31.9 % in elite basketball players [11] and also represents two thirds of all pathologies of the knee between these two sports [8].

The traditional model of “tendonitis” as an inflammatory process is now obsolete since the appearance of several publications, which have described the pathological process of the tendon as mainly degenerative (tendinosis) [12,13]. This is justified due to the absence of inflammatory cells, the presence of areas of collagen degeneration, myxoid degeneration and an increase in fundamental substance and is associated with a failure of the tendon repair process [12,13].

Achilles and patellar tendinopathy is a clinical diagnosis and typically is based on medical history and clinical findings. Imaging techniques: such as Color Doppler Sonography (CDS) and Magnetic Resonance Imaging (MRI) are valuable tools to confirm the diagnosis and provide guidance for treatment [14].

The tendon injury can occur in the tenotendinous region, as in the Achilles tendon. However, most of the tendon pathology and pain is located in the osteotendinous, such as elbow lateral epicondyle, patellar tendon and the medial epicondyle tendons and tendons in the groin [15]. While osteotendinous and tenotendinous and are morphologically different region in normal state, the occurrence of extracellular matrix pathology induced cellular changes are indistinguishable [16].

Achilles and patellar tendinopathy this is accompanied by an excessive nociceptive signalling from the tendon, causing pain and restricted mobility [17] he mechanisms behind these structural and neurological changes are not fully understood. A more recent theory ascribes part of the tendinosis changes to an increased production of biochemical agents, such as substance P (SP) [18] and NMDAR1 glutamate receptor [19,20].

Overall tendinopathies are characterized by prolonged, localized pain, associated with physical activity requiring cyclic mechanical stimuli. Patients respond poorly to most conservative treatments, however, a broad spectrum of disorders of the tendon within the concept of tendinopathy that share some common characteristics (paratendinitis, tendinitis, tendon overuse injuries, spontaneous tendon rupture, calcifying tendinitis) or gaps, often converge in the same tendon (Figure 1). In this sense, there is no single etiology and pathogenesis that can explain all these processes [15].

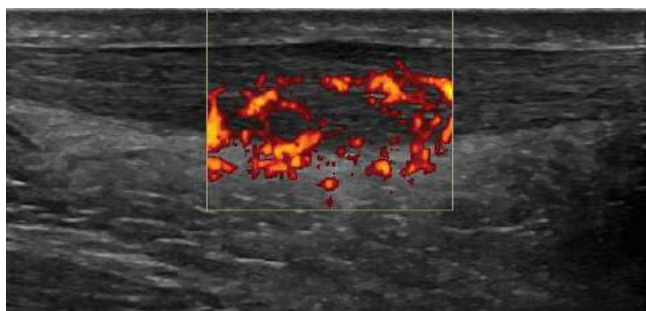
Treatment options have changed over the last decade in parallel to

**\*Corresponding author:** Jose Manuel Sánchez-Ibáñez, CEREDE Sports Orthopaedics Medicine and Rehabilitation, C/ Doctor Roux nº 8-10 bajos, Barcelona 08017, Spain, Tel: +34934523510; E-mail: [drsanchez@cerede.es](mailto:drsanchez@cerede.es)

**Received** September 11 2015; **Accepted** September 25 2015; **Published** October 06 2015

**Citation:** Sánchez-Ibáñez JM, Fernández ME, Moreno C, Martí D, Belón P (2015) Ultrasound-Guided EPI® Technique and Eccentric Exercise, New Treatment for Achilles and Patellar Tendinopathy Focused on the Region-Specific of the Tendon. Orthop Muscular Syst 4: 200. doi:[10.4172/2161-0533.1000200](https://doi.org/10.4172/2161-0533.1000200)

**Copyright:** © 2015 Sánchez-Ibáñez JM, et al. This is an open-access article distributed under the terms of the Creative Commons Attribution License, which permits unrestricted use, distribution, and reproduction in any medium, provided the original author and source are credited.



**Figure 1:** Longitudinal ultrasound view of Achilles tendinopathy. Gray-scale and power-doppler ultrasound showing the sonographic findings characteristic of Achilles tendinopathy. The sonogram reveals the hypoechoic, darken area of the Achilles tendon, tendon thickening and neovascularization.

the pathophysiological and histopathological findings in tendinopathy. Since the underlying pathology of chronic tendinopathy can be defined as a “defective healing response”, treatment should aim to encourage regeneration of the tendon, pain modulation and the restoration of the biomechanical properties [21].

Current treatment options include eccentric training, open or arthroscopic surgery, extracorporeal shockwave therapy, non-steroidal anti-inflammatory drugs, platelet-rich plasma injection and aprotinin. These studies have also suggested that, in general, patients with a worse functional status before treatment obtain inferior final outcomes. However, due to the limited evidence-based therapies, there are still several controversies regarding the real efficacy of these treatment modalities [22].

In this paper the authors will update the knowledge about Achilles and patellar tendinopathy and current treatments with EPI<sup>®</sup> technique and eccentric exercise focused on the region-specific of the tendon drawn from the existing literature as well as from their own experience dealing with this condition.

### Eccentric exercise therapy

Eccentric exercise therapy has shown to cause an upregulation of Insulin-like Growth Factor (IGF-I). This upregulation of IGF-I is associated with cellular proliferation and matrix remodelling within the tendon [23].

Programs of eccentric exercise have been proposed as a key element in strength training in rehabilitation because they can supposedly counteract the response of defective healing that apparently underlies tendinopathy by promoting the creation of collagen fibers within the tendon [24,25]. The literature places increasing emphasis on the importance of a proper choice of the load used [26].

The continuum model in tendinopathy (reactive tendinopathy, tendon dysrepair and degenerative tendinopathy) provides a reasoned basis for believing that the protocol to be performed depends on the current clinical presentation [15]. The protocol proposed by Alfredson et al. is generally used [24] it consists of three sets of 15 repetitions, performed twice a day, seven days a week for 12 weeks.

Ohberg et al. [27] examined tendon structure by grey-scale ultrasound in 26 tendons with Achilles tendinosis, which had been treated with eccentric exercise. Remarkably, after a mean follow up of 3.8 years, 19 of 26 tendons had a more normalised structure, as gauged

by their thickness and by the reduction of hypoechoic areas.

Visnes et al. [28] suggested that eccentric training had a positive effect on patellar tendinopathy and recommended that athletes suspend sports activity during rehabilitation.

The gradual progression from eccentric- concentric to eccentric followed by a faster loading can benefit patients with Achilles tendinopathy can not start with a program proposed by eccentric Alfredson et al [24] due to pain or weakness of the sural triceps muscle [29].

Isoinertial eccentric training (YoYoTechnology AB, Stockholm, Sweden) resulted in an improvement of muscle function and reduced pain in patients with patellar tendinopathy [30]. The combination of EPI<sup>®</sup> technique and isoinertial eccentric exercise offers good results in the treatment patellar tendinopathy [31].

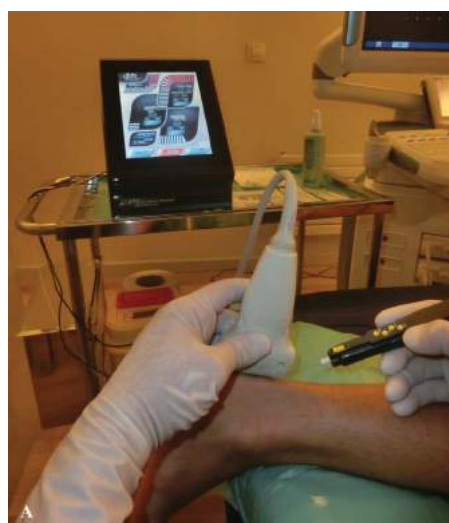### Ultrasound-guided EPI<sup>®</sup> technique

In recent years, the intratissue percutaneous electrolysis (EPI<sup>®</sup>) technique has become more relevant in the scientific literature [31-33] given the good results yielded in the treatment of degenerative tendinopathy in comparison to other previous conservative treatments.

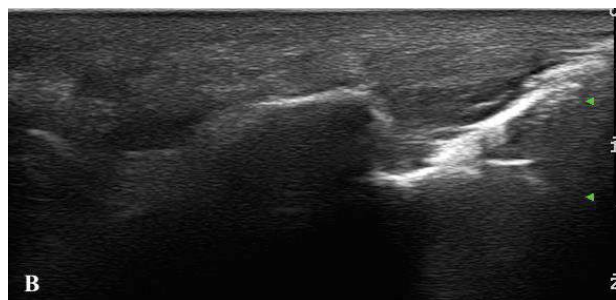
This technique, created by Sánchez-Ibáñez JM [34,35] and who have over 15 years experience in its use, uses a flow of cathodic current directed exclusively to the area of degenerated tendon through an ultrasound guided needle that brings about an organic reaction that leads to rapid regeneration of the degenerated tendon.

The application of EPI<sup>®</sup> technique produces a non-thermal electrochemical reaction centered on degenerated tissue (tendinosis). This leads to a controlled local inflammatory reaction that leads to the regeneration of damaged tissue [33,36].

The EPI<sup>®</sup> technique (Figure 2) achieves a very localized organic reaction in the clinical focus by using a specially designed EPI<sup>®</sup> device for this purpose (EPI Advanced Medicine<sup>®</sup>, Barcelona, Spain. EPI<sup>®</sup> technique videos online: [www.epiadvanced.com](http://www.epiadvanced.com)), which leads to the rapid regeneration of degenerated tissue. This leads to the production of new immature collagen fibers that become mature by means of eccentric stimulus [32], thereby obtaining good results in the short and



**Figure 2A:** Treatment of Achilles tendinopathy with ultrasound-guided EPI<sup>®</sup> technique (EPI Advanced Medicine<sup>®</sup>, Barcelona, Spain).



**Figure 2B:** Longitudinal ultrasound view of Achilles tendinopathy. Treatment is directed exclusively to the area of tendon injury. Note the non-thermal electrochemical reaction (white area) produced on the tip of the needle, just in the area of damaged tissue.

long-term in terms of pain and function.

In experimental studies with human tendon injury, there has been a disproportionate expression of certain cytokines and matrix metalloproteinase (MMPs), prostaglandin E2 (PGE2), interleukin -6 (IL-6) and interleukin -1b ( IL-1b ) [37,38]. IL- 1b in turn increases the production of matrix metalloproteinase -1 (MMP-1), matrix metalloproteinase -3 (MMP-3) and prostaglandin E2 (PGE-2) [39].

A recent experimental study [33] showed that with the use of ultrasound-guided EPI technique in patellar tendinopathy increase of anti-inflammatory proteins, like peroxisome proliferator-activated receptor gamma (PPAR- $\gamma$ ). These proteins play a key role in the inhibition of expression of proinflammatory molecules secreted by macrophages, such as tumor necrosis factor alpha (TNF- $\alpha$ ), IL-6 and IL-1 $\beta$ , thus producing in the treated tissue a highly beneficial molecular response during degenerative tendinopathy. This, in turn, results in an increase of the expression of vascular endothelial growth factor (VEGF) and vascular endothelial growth factor receptor 2 (VEGFR-2), mediators responsible for angiogenesis anti-inflammatory response. The EPI technique makes for the activation of molecular and cellular mechanisms of the tendon responsible for phagocytosis and the regeneration of degenerated tissue [33,36].

In recent research [31] to evaluate the therapeutic effects EPI technique and eccentric exercise on the patellar tendinopathy. The primary outcome measure was knee function using the Victorian Institute of Sport Assessment-Patella (VISA-P) score, a specific validated questionnaire to quantify pain and knee function and ability to play sport in patients with patellar tendinopathy [40,41]. The VISA-P score ranged from a maximum of 100 in asymptomatic patients to the theoretical minimum of 0. The authors of the score suggested that a score between 80 and 100 points might be considered as the optimal outcome category. Functional evaluation was further assessed with Blazina's classification [42]. This classification categorizes the symptomatic patients as in phase I (pain only after activity), phase II (discomfort during activity), phase III (pain during activity that interferes with participation) and phase IV (complete tendon disruption). The Tegner score was also used to assess the influence of the treatment in terms of restoring the previous sports activity level. All the written questionnaires were personally filled out by all patient before treatment, at the end of the treatment (at 3-month) and at the 2-year follow-up. The questionnaires corresponding to the 5 and 10 year follow-up evaluations were all filled out through a telephone interview. Patient satisfaction was measured according to the Roles and Maudsley score [43]. In this score, patients are classified as Excellent (no pain,

full movement and full activity), Good (occasional discomfort, full movement and full activity), Fair (some discomfort after prolonged activity) or Poor (pain limiting activities). The results documented were good and stable with the VISA-P score, Tegner scores and Roles and Maudsley score, and terms of clinical and functional improvement in patellar tendinopathy and providing a follow-up of 10 year.

In recent research [44] to evaluate the therapeutic effects EPI technique and eccentric exercises on the Achilles tendinopathy. A prospective study of 39 patients with Achilles tendinopathy was carried out. The patients were evaluated using the Victoria Institute of Sports Assessment - Achilles (VISA-A) score and the Foot and Ankle Disability Index for Sport scale (FADI); at the beginning of the study and after being monitored for 3 months. At the beginning of the study, the VISA-A score was an average of  $47 \pm 19.8$  (mean  $\pm$  SD ; ) and after being monitored for 3 months the score was an average of  $90.8 \pm 5.5$  (mean  $\pm$  SD), showing statistically significant differences ( $p < 0.001$ ). The results of the FADI showed that the average score at the beginning was  $64.5 \pm 26.9$  (mean  $\pm$  SD) and after 3 months it was  $123 \pm 1.5$  (mean  $\pm$  SD). Statistically significant differences were identified ( $p < 0.001$ ). The use of the EPI technique in combination with eccentric exercise in Achilles tendinopathy has shown evidence of a significant improvement in terms of pain and function. Not many sessions are required and the treatment time is short. The procedure has proven to be safe.

## Discussion

Treatment of Achilles and patellar tendinopathy is a subject of frequent debate in sports medicine and physiotherapy. Multiple techniques have been described for their treatment and although some of them [31,45-48].

To date, there is no consensus on the optimal treatment of Achilles and patellar tendinopathy. It has been suggested that the incomplete understanding of the underlying mechanisms (etiology of the condition) limits the ability to develop effective treatment strategies [49].

Doubts have mainly centered on the fact that there are few controlled prospective studies that analyze all aspects of tendinosis, and few studies that investigate the early stages of these processes and their healing mechanisms. The exact mechanism by which tendinopathy develops in humans remains the target of numerous investigations. A variety of degenerative characteristics associated tendinopathies, including accumulation glycosaminoglycan (GAG), calcification and lipid accumulation nerve damage and hyperinnervation, is one of the theories whose publications are scarce, despite its special interest in explaining the possible pathophysiological mechanisms of pain in tendinopathy [50].

In several studies it has been shown that there is a correlation between tendinopathy and hyperinnervation, citing that the production of Nerve Growth Factor (NGF) and the corresponding hyperinnervation could be induced by repetitive ischemic crisis in osteotendinous union [51,52]. This growth of nerve fibers, which causes chronic pain, could be part of a process of abnormal tissue repair, preceded by repetitive microtrauma [53].

Despite its prevalence, the precise pathogenic mechanisms of tendinopathy are not clear and, as a result, current treatments of tendinopathies are largely empirical and not always efficient [15,54]. The continuum model of tendon pathology was proposed to provide a model for the staging of tendon pathology and to assist clinicians in managing this often complex condition. The model presents clinical, histological and imaging evidence for the progression of tendon

pathology as a three-stage continuum: reactive tendinopathy, tendon disrepair and degenerative tendinopathy [15].

One of the clinical effects that eccentric exercises might have in tendinopathy is in pain modulation due to changes in glutamate content or in the central nervous system with increased activation of inhibitory neurons and cortical reorganization [48,55]. There is little evidence that isolated eccentric exercise reduces pain in tendinopathy compared with concentric exercise [56].

It is considered that hypoxia could be responsible for neovascularization in tendinopathies, capillary flow and post-capillary pressure decreased following 12 weeks of eccentric loading [57].

In the treatment of tendinopathy, there is conflicting evidence that eccentric exercises are superior to other load programs [56]. Eccentric work on an inclined plane did not improve functional outcomes when it was done during a competitive season in volleyball [58]. In another study, continuous sporting activity did not compromise clinical outcomes at 12 months, as long as the sport was introduced incrementally ensuring minimal pain during and after loading [59]. Eccentric decline squat training and heavy slow resistance training showed good long-term clinical results, and heavy slow resistance training also resulted in advantages in pathological improvement and increased collagen turnover [60].

Some authors have demonstrated better results with eccentric exercise on corporeal tendinopathies in comparison with enthesopathies [22].

On the other hand, maximal eccentric loading may be best for some groups of patients and permit adaptive changes in the tendon [30].

Despite the fact that the eccentric muscle workout has become the dominant conservative strategy in treating Achilles and patellar tendinopathy, up to 45% of patients do not respond to this treatment [61].

A recent study suggests that sedentary subjects with Achilles tendinopathy may show less promising results with eccentric exercise therapy compared to athletic subjects [62].

Despite some good results reported with eccentric programmes [61,63], it is still unclear as to the more effective exercise protocol, its frequency, load and dosage.

Despite over 15 years of experience in the use of the EPI® technique and its widespread deployment in sporting clubs around the world, this technique has grown in relative to scientific dissemination in recent years [31-33].

The EPI® technique is contraindicated mainly in patients with tumors, articular or systemic infection and bleeding disorders [34].

An experimental study showed that after application of the degenerated tendon EPI® technique, an increase in anti-inflammatory proteins, like PPAR- $\gamma$  has been observed after treatment with the EPI® technique. These proteins play a key role in the inhibition of expression of proinflammatory molecules secreted by macrophages, such as TNF- $\alpha$ , IL-6 and IL-1 $\beta$  [64] thus producing in the treated tissue a highly beneficial molecular response during tendinopathy. This, in turn, results in an increase of the expression of VEGF and VEGFR-2, mediators responsible for angiogenesis anti-inflammatory response [65,66].

In another recent study by Sánchez-Ibáñez and co-workers [31] reported that treatment with the ultrasound-guided EPI® technique

and eccentric exercises in patellar tendinopathy resulted in a great improvement in knee function and a rapid return to the previous level of activity after few sessions. The limitations of this study are the absence of a control group.

References to the use of the EPI® technique in combination with eccentric exercise can be found in the literature. In those cases the EPI® technique focuses on biological tissue recovery, leaving the functional recovery of tissue biomechanics to eccentric exercise [31].

## Conclusions

Achilles and patellar tendinopathy is a condition that causes many patients significant pain and disability. Currently, the aetiology of tendinopathy is still unclear, it is multifactorial, and influenced by intrinsic and extrinsic factors. Tendinopathy often becomes chronic because the exact pathogenesis remains largely unknown. Physicians and physiotherapist have a variety of therapeutic options available to treat tendinopathies but, in each case, there is a lack of evidence supporting their use as the gold standard treatment.

The combination of EPI® technique and eccentric exercise offers good results in terms of clinical and functional improvement in Achilles and patellar tendinopathy with low morbidity in a half study period.

## Acknowledgements

We are grateful to Julita Cuquerella and David MacManus for your help in editing the manuscript.

## Author Contributions

Wrote the first draft of the manuscript: JMS, MEF, CM, DM, PB. Contributed to the writing of the manuscript: JMS, MEF, CM, DM, PB. Agree with manuscript results and conclusions: JMS, MEF, CM, DM, PB. Jointly developed the structure and arguments for the paper: JMS, MEF, CM, DM, PB. Made critical revisions and approved final version: JMS, MEF, CM, DM, PB. All authors reviewed and approved the final manuscript.

## Disclosures and Ethics

The authors declare that one author has the patent for the EPI devices® and one author are the creators of the EPI® Technique.

## References

1. Scott A, Ashe MC (2006) Common tendinopathies in the upper and lower extremities. *Curr Sports Med Rep* 5: 233-241.
2. Tresoldi I, Oliva F, Benvenuto M, Fantini M, Masuelli L, et al. (2013) Tendon's ultrastructure. *Muscles Ligaments Tendons J* 3: 2-6.
3. Kannus P (1997) Etiology and pathophysiology of chronic tendon disorders in sports. *Scand J Med Sci Sports* 7: 78-85.
4. Kvist M (1994) Achilles tendon injuries in athletes. *Sports Med* 18: 173-201.
5. Maffulli N, Wong J, Almekinders LC (2003) Types and epidemiology of tendinopathy. *Clin Sports Med* 22: 675-692.
6. Butler DL, Gooch C, Kinneberg KR, Boivin GP, Galloway MT, et al. (2010) The use of mesenchymal stem cells in collagen-based scaffolds for tissue-engineered repair of tendons. *Nat Protoc* 5: 849-863.
7. Hess GW (2010) Achilles tendon rupture: a review of etiology, population, anatomy, risk factors, and injury prevention. *Foot Ankle Spec* 3: 29-32.
8. Scott A, Ashe MC (2006) Common tendinopathies in the upper and lower extremities. *Curr Sports Med Rep* 5: 233-241.
9. Fredberg U and Stengaard-Pedersen K (2008) Chronic tendinopathy tissue pathology, pain mechanisms, and etiology with a special focus on inflammation. *Scandinavian Journal of Medicine & Science in Sports* 18: 3-15.
10. Ferretti A, Papandrea P, Conteduca F (1990) Knee injuries in volleyball. *Sports Med* 10: 132-138.
11. Lian OB, Engebretsen L, Bahr R (2005) Prevalence of jumper's knee among

- elite athletes from different sports: a cross-sectional study. *Am J Sports Med* 33: 561-567.
12. Alfredson H, Lorentzon R (2002) Chronic tendon pain: no signs of chemical inflammation but high concentrations of the neurotransmitter glutamate. Implications for treatment? *Curr Drug Targets* 3: 43-54.
13. Cook JL, Khan KM, Maffulli N, Purdam C (2000) Overuse tendinosis, not tendinitis part 2: applying the new approach to patellar tendinopathy. *Phys Sportsmed* 28: 31-46.
14. Warden SJ, Kiss ZS, Malara FA, Ooi AB, Cook JL, et al. (2007) Comparative accuracy of magnetic resonance imaging and ultrasonography in confirming clinically diagnosed patellar tendinopathy. *Am J Sports Med* 35: 427-436.
15. Cook JL, Purdam CR (2009) Is tendon pathology a continuum? A pathology model to explain the clinical presentation of load-induced tendinopathy. *Br J Sports Med* 43: 409-416.
16. Maffulli N, Testa V, Capasso G, Ewen SW, Sullo A, et al. (2004) Similar histopathological picture in males with Achilles and patellar tendinopathy. *Med Sci Sports Exerc* 36: 1470-1475.
17. Kader D, Saxena A, Movin T, Maffulli N (2002) Achilles tendinopathy: some aspects of basic science and clinical management. *Br J Sports Med* 36: 239-249.
18. Backman LJ, Andersson G, Wennstig G, Forsgren S, Danielson P (2011) Endogenous substance P production in the Achilles tendon increases with loading in an in vivo model of tendinopathy-peptidergic elevation preceding tendinosis-like tissue changes. *J Musculoskelet Neuronal Interact* 11: 133-140.
19. Alfredson H, Forsgren S, Thorsen K, Fahlström M, Johansson H, et al. (2001) Glutamate NMDAR1 receptors localised to nerves in human Achilles tendons. Implications for treatment? *Knee Surg Sports Traumatol Arthrosc* 9: 123-126.
20. Molloy TJ, Kemp MW, Wang Y, Murrell GA (2006) Microarray analysis of the tendinopathic rat supraspinatus tendon: glutamate signaling and its potential role in tendon degeneration. *J Appl Physiol* (1985) 101: 1702-1709.
21. Cook JL, Khan KM (2001) What is the most appropriate treatment for patellar tendinopathy? *Br J Sports Med* 35: 291-294.
22. Andres BM, Murrell GA (2008) Treatment of tendinopathy: what works, what does not, and what is on the horizon. *Clin Orthop Relat Res* 466: 1539-1554.
23. Olesen JL, Heinemeier KM, Gemmer C, Kjaer M, Flyvbjerg A, et al. (2007) Exercise-dependent IGF-I, IGF-BPs, and type I collagen changes in human peritendinous connective tissue determined by microdialysis. *J Appl Physiol* (1985) 102: 214-220.
24. Alfredson H, Pietilä T, Jonsson P, Lorentzon R (1998) Heavy-load eccentric calf muscle training for the treatment of chronic Achilles tendinosis. *Am J Sports Med* 26: 360-366.
25. Mafi N, Lorentzon R, Alfredson H (2001) Superior short-term results with eccentric calf muscle training compared to concentric training in a randomized prospective multicenter study on patients with chronic Achilles tendinosis. *Knee Surg Sports Traumatol Arthrosc* 9: 42-47.
26. Magnusson SP, Langberg H, Kjaer M (2010) The pathogenesis of tendinopathy: balancing the response to loading. *Nat Rev Rheumatol* 6: 262-268.
27. Ohberg L, Lorentzon R, Alfredson H (2004) Eccentric training in patients with chronic Achilles tendinosis: normalised tendon structure and decreased thickness at follow up. *Br J Sports Med* 38: 8-11.
28. Visnes H, Bahr R (2007) The evolution of eccentric training as treatment for patellar tendinopathy (jumper's knee): a critical review of exercise programmes. *Br J Sports Med* 41: 217-223.
29. Silbernagel KG, Thomeé R, Thomeé P, Karlsson J (2001) Eccentric overload training for patients with chronic Achilles tendon pain--a randomised controlled study with reliability testing of the evaluation methods. *Scand J Med Sci Sports* 11: 197-206.
30. Romero-Rodriguez D, Gual G, Tesch PA (2011) Efficacy of an inertial resistance training paradigm in the treatment of patellar tendinopathy in athletes: a case-series study. *Phys Ther Sport* 12: 43-48.
31. Abat F, Gelber P, Polidori F, Monllau JC, Sánchez-Ibáñez JM (2014) Clinical results after ultrasound-guided intratissue percutaneous electrolysis (EPI®) and eccentric exercise in the treatment of patellar tendinopathy over a 10-year follow-up. *Knee Surgery, Sports Traumatology, Arthroscopy* 23:1046-1052.
32. Abat F, Diesel WJ, Gelber P, Polidori F, Monllau JC, et al. (2014) Effectiveness of the Intratissue Percutaneous Electrolysis (EPI®) technique and isoinertial eccentric exercise in the treatment of patellar tendinopathy at two years follow-up. *Muscles, Ligaments and Tendons Journal* 4: 188-193.
33. Abat F, Valles SL, Paredes-Brunet P, Polidori F, Gelber PE, et al. (2014) Molecular repair mechanisms using the Intratissue Percutaneous Electrolysis technique in patellar tendinitis. *Rev Esp Cir Ortop Traumatol* 58: 201-205.
34. Sánchez-Ibáñez JM (2013) Clinical evolution in the chronic patellar enthesopathy treatment by EPI® Technique guided-ultrasound - Study of several cases in sports population. [PhD. Thesis], Universidad de León. León. Spain.
35. Sánchez-Ibáñez JM, Colmena C, Benabent J, Garcia-Herreros S, Valles SL (2013) New Technique in Tendon Sport Recovery. Percutaneous Electrolysis Intratissue (EPI®). *Int J Phys Med Rehabil* 1: 113.
36. Abat F, Valles SL, Gelber PE, Polidori F, Jorda A, García-Herreros S, et al. (2015) An experimental study of muscular injury repair in a mouse model of notexin-induced lesion with EPI® technique. *BMC Sports Science, Medicine and Rehabilitation* 7: 7.
37. Skutek M, van Griensven M, Zeichen J, Brauer N, Bosch U (2001) Cyclic mechanical stretching enhances secretion of Interleukin 6 in human tendon fibroblasts. *Knee Surg Sports Traumatol Arthrosc* 9: 322-326.
38. Tsuzaki M, Bynum D, Almekinders L, Yang X, Faber J, et al. (2003) ATP modulates load-inducible IL-1beta, COX 2, and MMP-3 gene expression in human tendon cells. *J Cell Biochem* 89: 556-562.
39. Tsuzaki M, Guyton G, Garrett W, Archambault JM, Herzog W, et al. (2003) IL-1 beta induces COX2, MMP-1, -3 and -13, ADAMTS-4, IL-1 beta and IL-6 in human tendon cells. *J Orthop Res* 21: 256-264.
40. Hernandez-Sanchez S, Hidalgo MD, Gomez A (2011) Cross-cultural adaptation of VISA-P score for patellar tendinopathy in Spanish population. *J Orthop Sports Phys Ther* 41: 581-591.
41. Visentini PJ, Khan KM, Cook JL, Kiss ZS, Harcourt PR, et al. (1998) The VISA score: an index of severity of symptoms in patients with jumper's knee (patellar tendinosis). Victorian Institute of Sport Tendon Study Group. *J Sci Med Sport* 1: 22-28.
42. Roels J, Martens M, Mulier JC, Burssens A (1978) Patellar tendinitis (jumper's knee). *Am J Sports Med* 6: 362-368.
43. Roles NC, Maudsley RH (1972) Radial tunnel syndrome: resistant tennis elbow as a nerve entrapment. *J Bone Joint Surg Br* 54: 499-508.
44. Sanchez-Ibáñez JM, Fernández ME, Segarra V, Marco J, Monllau JC, et al. (2014) Clinical results after ultrasound-guided intratissue percutaneous electrolysis (EPI®) and isoinertial exercise in the treatment of Achilles tendinopathy: 23.
45. Abat F, Sánchez-Ibáñez JM (2014) Patellar tendinopathy: A critical review of current therapeutic options. *OA Sports Medicine* 18; 2.
46. Rompe JD, Maffulli N (2007) Repetitive shock wave therapy for lateral elbow tendinopathy (tennis elbow): a systematic and qualitative analysis. *Br Med Bull* 83: 355-378.
47. Andia I, Abate M (2012) Platelet rich plasma injections for tendinopathy and osteoarthritis. *Int J Clin Rheumatol* 7: 397-412.
48. Alfredson H, Ohberg L, Forsgren S (2003) Is vasculo-neural ingrowth the cause of pain in chronic Achilles tendinosis? An investigation using ultrasonography and colour Doppler, immunohistochemistry, and diagnostic injections. *Knee Surg Sports Traumatol Arthrosc* 11: 334-338.
49. Cannell LJ, Taunton JE, Clement DB, Smith C, Khan KM (2001) A randomised clinical trial of the efficacy of drop squats or leg extension/leg curl exercises to treat clinically diagnosed jumper's knee in athletes: pilot study. *Br J Sports Med* 35: 60-64.
50. Riley G (2004) The pathogenesis of tendinopathy. A molecular perspective. *Rheumatology (Oxford)* 43: 131-142.
51. Danielson P, Andersson G, Alfredson H, Forsgren S (2008) Marked sympathetic component in the perivascular innervation of the dorsal paratendinous tissue of the patellar tendon in arthroscopically treated tendinosis patients. *Knee Surg Sports Traumatol Arthrosc* 16: 621-626.
52. Bagge J, Lorentzon R, Alfredson H, Forsgren S (2009) Unexpected presence of the neurotrophins NGF and BDNF and the neurotrophin receptor p75 in the

- tendon cells of the human Achilles tendon. *Histol Histopathol* 24: 839-848.
53. Danielson P, Alfredson H, Forsgren S (2007) In situ hybridization studies confirming recent findings of the existence of a local nonneuronal catecholamine production in human patellar tendinosis. *Microsc Res Tech* 70: 908-911.
54. Wang JH, Iosifidis MI, Fu FH (2006) Biomechanical basis for tendinopathy. *Clin Orthop Relat Res* 443: 320-332.
55. Wand BM, O'Connell NE (2008) Chronic non-specific low back pain - subgroups or a single mechanism? *BMC Musculoskelet Disord* 9: 11.
56. Jonsson P, Alfredson H (2005) Superior results with eccentric compared to concentric quadriceps training in patients with jumper's knee: a prospective randomised study. *Br J Sports Med* 39: 847-850.
57. Knobloch K, Kraemer R, Jagodzinski M, Zeichen J, Meller R, et al. (2007) Eccentric training decreases paratendon capillary blood flow and preserves paratendon oxygen saturation in chronic achilles tendinopathy. *J Orthop Sports Phys Ther* 37: 269-276.
58. Visnes H, Hoksrud A, Cook J, Bahr R (2005) No effect of eccentric training on jumper's knee in volleyball players during the competitive season: a randomized clinical trial. *Clin J Sport Med* 15: 227-234.
59. Silbernagel KG, Thomee R, Eriksson BI, et al. (2007) Continued sports activity, using a pain-monitoring model, during rehabilitation in patients with Achilles tendinopathy: a randomized controlled study. *Am J Sports Med* 35: 897-906.
60. Kongsgaard M, Kovanen V, Aagaard P, Doessing S, Hansen P, et al. (2009) Corticosteroid injections, eccentric decline squat training and heavy slow resistance training in patellar tendinopathy. *Scand J Med Sci Sports* 19: 790-802.
61. Malliaras P, Barton CJ, Reeves ND, Langberg H (2013) Achilles and patellar tendinopathy loading programmes: a systematic review comparing clinical outcomes and identifying potential mechanisms for effectiveness. *Sports Med* 43: 267-286.
62. Sayana MK, Maffulli N (2007) Eccentric calf muscle training in non-athletic patients with Achilles tendinopathy. *J Sci Med Sport* 10: 52-58.
63. Silbernagel KG, Brorsson A, Lundberg M (2011) The majority of patients with Achilles tendinopathy recover fully when treated with exercise alone: a 5-year follow-up. *Am J Sports Med* 39: 607-613.
64. Jiang C, Ting AT, Seed B (1998) PPAR-gamma agonists inhibit production of monocyte inflammatory cytokines. *Nature* 391: 82-86.
65. Sahin H, Tholema N, Petersen W, Raschke MJ, Stange R (2012) Impaired biomechanical properties correlate with neoangiogenesis as well as VEGF and MMP-3 expression during rat patellar tendon healing. *J Orthop Res* 30: 1952-1957.
66. Nakama LH, King KB, Abrahamsson S, Rempel DM (2006) VEGF, VEGFR-1, and CTGF cell densities in tendon are increased with cyclical loading: An in vivo tendinopathy model. *J Orthop Res* 24: 393-400.

**Citation:** Sánchez-Ibáñez JM, Fernández ME, Moreno C, Martí D, Belón P (2015) Ultrasound-Guided EPI® Technique and Eccentric Exercise, New Treatment for Achilles and Patellar Tendinopathy Focused on the Region-Specific of the Tendon. *Orthop Muscular Syst* 4: 200. doi:[10.4172/2161-0533.1000200](https://doi.org/10.4172/2161-0533.1000200)

### OMICS International: Publication Benefits & Features

#### Unique features:

- Increased global visibility of articles through worldwide distribution and indexing
- Showcasing recent research output in a timely and updated manner
- Special issues on the current trends of scientific research

#### Special features:

- 700 Open Access Journals
- 50,000 editorial team
- Rapid review process
- Quality and quick editorial, review and publication processing
- Indexing at PubMed (partial), Scopus, DOAJ, EBSCO, Index Copernicus and Google Scholar etc
- Sharing Option: Social Networking Enabled
- Authors, Reviewers and Editors rewarded with online Scientific Credits
- Better discount for your subsequent articles

Submit your manuscript at: <http://www.omicsonline.org/submission>